

Osteonecrosis of the Humeral Head After Intra-Articular Corticosteroid Injections in a Patient Receiving Dialysis

Hemodiyaliz Tedavisi Alan Bir Hastada Intraartiküler Kortikostreoid Enjeksiyonu Sonrası Gelişen Omuz Osteonekrozu

Nur Sacide SARAÇGİL COŞAR, Oya Ümit YEMİŞÇİ, Pınar ÖZTOP, Seval ERHAMAMCI*, Metin KARATAŞ
Baskent University, Faculty of Medicine, Department of Physical Medicine and Rehabilitation, Ankara, Turkey
*Baskent University, Faculty of Medicine, Department of Nuclear Medicine, Konya, Turkey

Summary

A 66-year-old woman with idiopathic chronic renal failure was admitted to our clinic for shoulder pain. Physical examination revealed a tender left shoulder with limitation of active and preservation of passive motion. Previous radiographic evaluation of the left shoulder revealed subchondral cystic lesions in the humeral head and, mild degenerative changes were detected by magnetic resonance imaging (MRI). Two intra-articular injections of methylprednisolone acetate 40 mg were administered to her shoulder at a four-month interval. Due to persistent shoulder pain, MRI of the shoulder was repeated and osteonecrosis of the humeral head was depicted. Osteonecrosis is a recognized complication of chronic renal failure in association with kidney transplantation or steroid therapy. *Turk J Phys Med Rehab 2011;57:101-3.*

Key Words: Intra-articular corticosteroid, osteonecrosis, shoulder

Özet

Sol omuz ağrısı şikayeti ile kliniğimize başvuran, idiopatik kronik böbrek yetmezliği olan 66 yaşındaki kadın hastanın fizik muayenesinde sol omuzda hassasiyet ile birlikte aktif eklem hareketlerinde kısıtlılık ve pasif eklem hareketleri korunmuş bulundu. Daha önceki radyolojik tetkikinde humerus başında subkondral kist ve manyetik rezonans görüntüleme (MRG)'sinde hafif dejeneratif değişiklikleri vardı. Hastaya 4 ay ara ile iki defa intraartiküler 40 mg methylprednisolone acetate enjeksiyonu yapılmıştı. Hastanın enjeksiyon sonrası devam eden omuz ağrısını değerlendirmek için çekilen MRG sonrası omuzda, humerus başında osteonekroz tesbit edildi. Osteonekroz, kronik böbrek yetmezliğinde, böbrek transplantasyonu ve steroid tedavisi ile ilişkili olarak, karşılaşılan bir komplikasyondur. *Türk Fiz Tıp Rehab Derg 2011;57:101-3.*

Anahtar Kelimeler: Intraartiküler kortikosteroid, osteonekroz, omuz

Introduction

Osteonecrosis is defined as the in situ death of a segment of bone (1). Most osteonecrosis cases are related to traumatic interruption of the blood supply to the bone, while nontraumatic cases are related to systemic disorders (2). The most commonly reported cause of nontraumatic osteonecrosis is corticosteroid therapy (3-5). Osteonecrosis following intra-articular corticosteroid injection of the hip and glenohumeral joint has been reported previously (6).

Case Report

A 66-year-old woman with idiopathic chronic renal failure presented to our outpatient clinic with a complaint of chronic, atraumatic onset of severe shoulder pain. She had a 6-year history of left shoulder pain aggravated by activity and limitation of motion, however, the intensity of pain had increased recently. There was no significant medical history other than idiopathic chronic renal failure, for which she was receiving maintenance hemodialysis for 10 years. There was no history of trauma,

systemic corticosteroid therapy, alcohol abuse, diabetes mellitus, transplantation, hyperlipidemia, significant hyperuricemia or hyperparathyroidism. Previously, two intra-articular injections of methylprednisolone acetate 40 mg were administered to her shoulder at a four-month interval in order to relieve pain.

On physical examination, she was afebrile and her vital signs were within normal range. Tenderness was present in the left shoulder with no sign of swelling or joint inflammation. Both active and passive range of motion of the shoulder provoked severe pain. Especially, active internal and external rotations of the shoulder were severely limited, while abduction and forward flexion were limited at 60°. Passive range of motion was relatively preserved. There was no neurological deficit. Laboratory investigation showed normal serum levels of calcium, phosphorus, alkaline phosphatase and parathyroid hormone. Antinuclear antibody was negative. No abnormality was found in the liver functions. Radiographic evaluation of the left shoulder was unremarkable except for a few subchondral cystic lesions in the humeral head (Figure 1) and, mild degenerative changes were reported by magnetic resonance imaging (MRI) studies performed prior to corticosteroid injections (Figure 2). MRI studies were repeated due to persistent pain and, increased signal intensity in the humeral head with contrast enhancement concordant with osteonecrosis was demonstrated (Figure 3 and 4). Bone scintigraphy was performed in order to assess the patient for osteonecrosis of other joints. Bone scan demonstrated an increased uptake of a technetium-99m-methylene diphosphonate (^{99m}Tc-MDP) in the left shoulder, but no areas of osteonecrosis were detected elsewhere in the skeleton.

Surgical intervention was planned and core decompression was carried out. The patient's shoulder pain relieved rapidly after surgery.

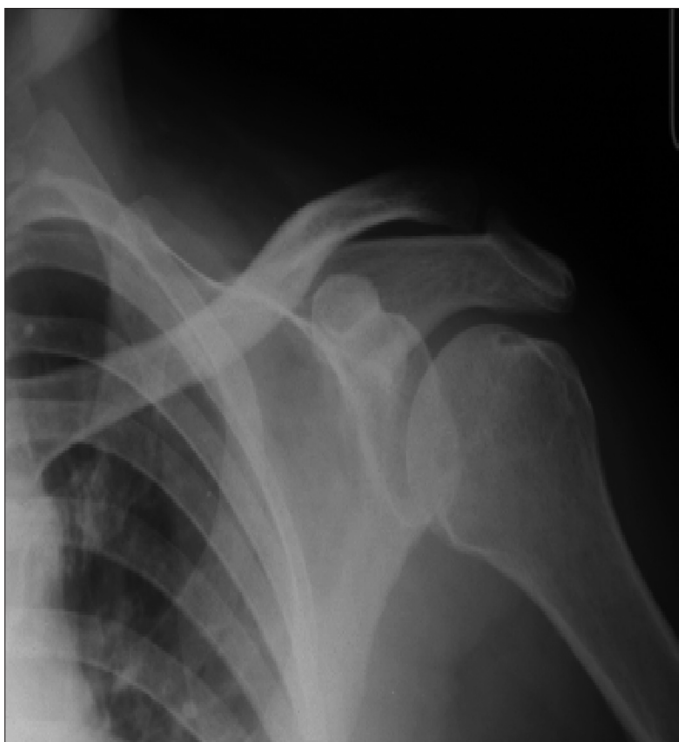

Figure 1. Radiograph of the left shoulder reveals subchondral cystic lesions in the humeral head.

Discussion

Osteonecrosis is a recognized complication of chronic renal failure in association with kidney transplantation or steroid therapy, reaching a prevalence rate of up to 30-80 % in various series (7-10). However, osteonecrosis is a rare complication in patients receiving chronic dialysis without known risk factors (11,12). Langevitz et al. (13) discussed the possible role of secondary hyperparathyroidism in the pathogenesis of osteonecrosis of the humeral head in these patients. However, there were no signs of secondary hyperparathyroidism in our case.

Laroche et al. (6) reported two cases with osteonecrosis of the femoral and humeral heads due to repeated intra-articular injections of long-acting corticosteroids in distant joints and iatrogenic cortisol excess. In our case, there was no evidence of osteonecrosis in distant joints, except for the left shoulder.

Later McCarty et al. (14) reported a case with osteonecrosis of both knees. They explained the cause of osteonecrosis as a result of repeated intra-articular corticosteroid injections in the same joints. Also, regional epiphyseal osteonecrosis was observed in children after intrasynovial corticosteroid injections (15).

In previous reports, the total dose of corticosteroid purportedly associated with osteonecrosis differs from 160 mg to 740 mg of triamcinolone (6,14). In a recent publication, Yamamoto et al. (16) described a case of osteonecrosis in the femoral head after a single injection of methylprednisolone acetate (80 mg) into the hip joint. It has been shown that the rate of osteonecrosis after the use of methylprednisolone was higher than after the use of triamcinolone (17). In our case, the total dose of corticosteroid was 80 mg of methylprednisolone given at a four-month interval.

Similar to the previous case reports, we considered that repeated intra-articular corticosteroid injections to the shoulder might have played an etiologic role in our case.

Conclusion

Nontraumatic osteonecrosis related to systemic disorders remains a diagnostic challenge, especially in defining the precise

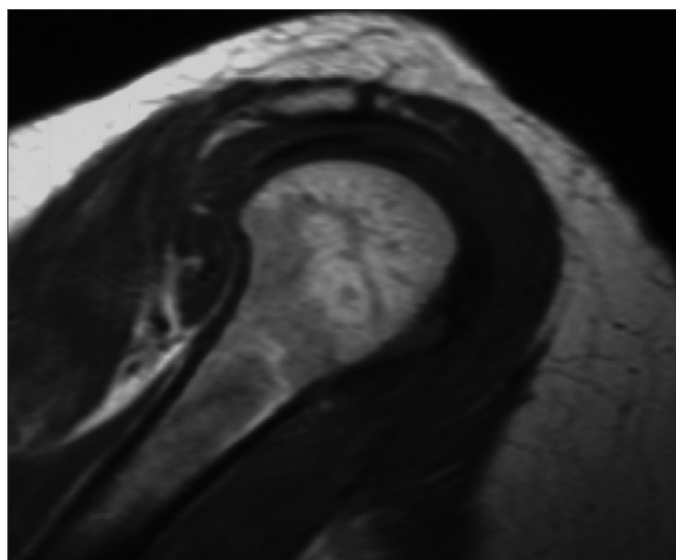


Figure 2. Sagittal T1 weighted image show mild degenerative changes of the humeral head .

cause of bone death. It is a rare complication in patients receiving chronic dialysis without any known risk factors, however, corticosteroid therapy is a major risk factor for increasing the development of osteonecrosis. It is difficult to predict which

patients will develop osteonecrosis as a consequence of glucocorticoid use, but comorbidities that increase the risk of osteonecrosis may play a role. In these patients, osteonecrosis must be considered in the differential diagnosis of persistent joint pain.

Our case report emphasizes the risk of repeated intra-articular injections of long-acting corticosteroids and call attention to the fact that little is known about the total dose of corticosteroid associated with osteonecrosis.

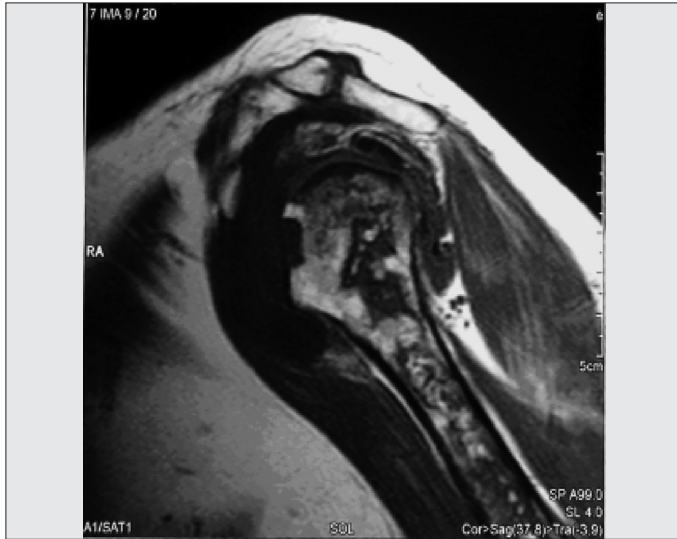


Figure 3. Sagittal T1 weighted image show extensive low signal abnormalities of the humeral epiphysis, metaphysis and diaphysis that indicate avascular necrosis.

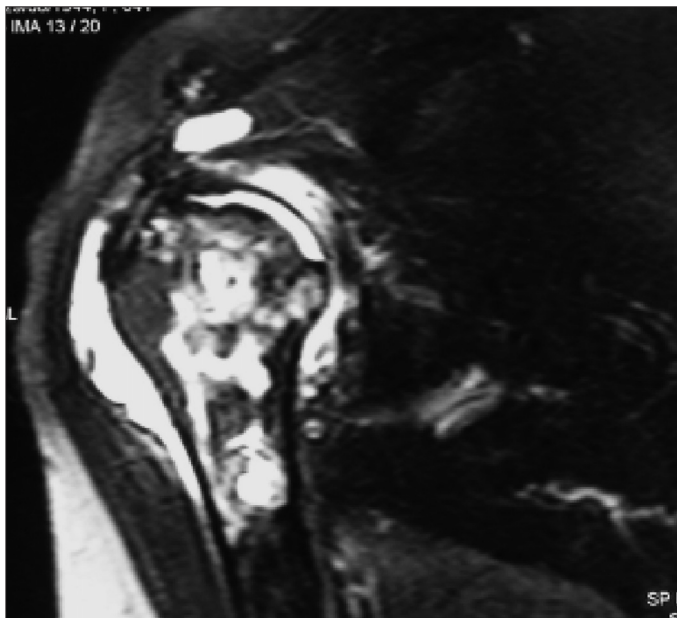

Figure 4. Coronal T2 weighted fat saturated image show severe osteonecrotic changes in the humeral head and increased signal abnormalities in the subdeltoid, subacromial and subscapular bursa.

References

1. Mankin HJ. Nontraumatic necrosis of bone (osteonecrosis). *N Engl J Med* 1992;326:1473-9.
2. Derk JT, DeHoratius RJ. Osteonecrosis. In: Koopman WJ, Moreland LW, editors. *Arthritis and allied conditions*. 15th Ed. Philadelphia, CN: Lippincott Williams and Wilkins; 2005. p. 2154-67.
3. Hungerford DS, Lennox DW. The importance of increased intraosseous pressure in the development of osteonecrosis of the femoral head: implications for treatment. *Orthop Clin North Am* 1985;16:635-54.
4. Jones JP Jr. Editorial comment: osteonecrosis. *Clin Orthop* 1978;130:2-4.
5. Hız Ö, Ünver H, Özkan Y, Yazmalar L, Tekeoğlu İ. Multifocal osteonecrosis in a case with systemic lupus erythematosus: original image. *J Med Sci* 2009;29:784-7.
6. Laroche M, Arlet J, Mazieres B. Osteonecrosis of the femoral and humeral heads after intraarticular corticosteroid injections. *J Rheumatol* 1990;17:549-51.
7. Potter DE, Genant HH, Salvatierra O. Avascular necrosis of bone after renal transplantation. *Am J Dis Child* 1978;132:1125-9.
8. Harrington KD, Murray WR, Kountz SC, Bezlen FO. Avascular necrosis of bone after renal transplantation. *J Bone Joint Surg Am* 1971;53:203-15.
9. Fisher DE, Beckel WH. Corticosteroid induced avascular necrosis. *J Bone Joint Surg Am* 1971;53:859-73.
10. Bailey GL, Griffiths HY, Mocelin AY, Gundy DH, Hampers CL, Merrill YP. Avascular necrosis of the femoral head in patients on chronic hemodialysis. *Trans Am Soc Artif Intern Organs* 1972;18:401-4.
11. Brown EA, Gower PE. Joint problems in patients on maintenance hemodialysis. *Clin Nephrol* 1982;18:247-50.
12. Menery K, Braunstein E, Brown M, Swartz R, Brown C, Fox JH. Musculoskeletal symptoms related to arthropathy in patients receiving dialysis. *J Rheumatol* 1988;15:1848-53.
13. Langevitz P, Buskila D, Stewart J, Sherrard DJ, Hercz G. Osteonecrosis in patients receiving dialysis: report of two cases and review of the literature. *J Rheumatol* 1990;17:402-6.
14. McCarty DJ, McCarty G, Carrera G. Intraarticular corticosteroids possibly leading to local osteonecrosis and marrow fat induced synovitis. *J Rheumatol* 1991;18:1091-4.
15. Sparling M, Malleson PN, Wood B, Petty RC. Radiographic follow-up of joints injected with triamcinolone hexacetonide for the management of childhood arthritis. *Arthritis Rheum* 1990;33:821-6.
16. Yamamoto T, Schneider R, Iwamoto Y, Bullough PG. Rapid destruction of the femoral head after a single intraarticular injection of corticosteroid into the hip joint. *J Rheumatol* 2006;33:1701-4.
17. Miyanishi K, Yamamoto T, Irisa T, Motomura G, Jingushi S, Sueishi K, Iwamoto Y. Effects of different corticosteroids on the development of osteonecrosis in rabbits. *Rheumatology (Oxford)* 2005;44:332-6.