

The effect of activation of thoracolumbar fascia on the thickness of abdominal muscles: An ultrasonographic study

Zeynep Turan , Özden Özyemişçi-Taşkiran

Department of Physical Medicine and Rehabilitation, Koç University School of Medicine, İstanbul, Türkiye

Received: December 02, 2020 Accepted: March 04, 2021 Published online: June 01, 2022

ABSTRACT

Objectives: This study aims to evaluate the changes in the ultrasonographic thickness of transversus abdominis and internal oblique muscles during bridge with arm extension compared to bridge and abdominal hollowing.

Patients and methods: Between March 1st, 2019 and March 29th, 2019, a total of 30 healthy individuals (15 males, 15 females; mean age: 28.8±8.1 years; range, 21 to 52 years) among hospital staff were included. Thickness of transversus abdominis, internal, and external oblique muscles of the participants were evaluated using ultrasound during four positions (rest, abdominal hollowing, bridge, and bridge with arm extension).

Results: The mean body mass index was 23.8±4.1 kg/m². The thickness of transversus abdominis and internal oblique muscles increased during all positions (p<0.001), compared to rest. The thickness during bridge with arm extension was greater than abdominal hollowing and bridge.

Conclusion: Co-activation of latissimus dorsi and gluteus maximus muscles during abdominal contraction increases the thickness of internal oblique and transversus abdominis muscles greater than abdominal contraction alone or co-activation of gluteus maximus alone. Simultaneous isometric contraction of latissimus dorsi muscle may enhance abdominal muscle function.

Keywords: Abdominal muscles, exercise, fascia, ultrasonography.

Spinal stability is crucial in maintaining healthy posture.^[1] Muscles stiffen the spine and increase its stability.^[1] Core is a muscular box built from diaphragm, abdominal, paraspinal, gluteal and pelvic floor muscles which function in coordination for stabilization.^[2-4] Deep core muscles which consist of transversus abdominis (TrA), internal oblique (IO), multifidi and pelvic floor muscles, control intersegmental motion and respond to postural and extrinsic load changes.^[4-6] Trunk and extremity muscles form a complex dynamic system via fascial connections; therefore, in core training programs, muscular chains may be considered rather than muscles in isolation.^[7] The thoracolumbar fascia (TLF)

provides connection between muscles of the core and extremities.^[8]

Fundamental exercise of core stabilization is abdominal hollowing by the proper activation of TrA and IO. During abdominal hollowing, force generated by contraction of TrA in the middle layer of TLF stretches the posterior layer of TLF, as these layers fuse each other at lateral raphe.^[9] Stretching of posterior layer results in activation of the multifidi that it contains. This co-activation of TrA, IO, and multifidi produce stabilization without any spinal movement. Back functional line links latissimus dorsi (LD) and gluteus maximus (GMax) through TLF

Corresponding author: Zeynep Turan, MD. Koç Üniversitesi Tıp Fakültesi, Fiziksel Tıp ve Rehabilitasyon Anabilim Dalı, 34010 Zeytinburnu, İstanbul, Türkiye.

e-mail: drzynptrn@gmail.com

Cite this article as:

Turan Z, Özyemişçi-Taşkiran Ö. The effect of activation of thoracolumbar fascia on the thickness of abdominal muscles: An ultrasonographic study. Turk J Phys Med Rehab 2022;68(2):169-174.

©2022 All right reserved by the Turkish Society of Physical Medicine and Rehabilitation

This is an open access article under the terms of the Creative Commons Attribution-NonCommercial License, which permits use, distribution and reproduction in any medium, provided the original work is properly cited and is not used for commercial purposes (<http://creativecommons.org/licenses/by-nc/4.0/>).



causing tensegrity-like network.^[10] Bridge exercise activates this functional line via activating GMax. Adding arm extension also activates LD in this chain.^[11] To the best of our knowledge, there is no study showing if deep core muscles are activated better while doing these exercises; therefore, it is still unknown.

Activation of abdominal muscles can be demonstrated using electromyography that is invasive and time-consuming^[12-15] or using ultrasonography that gives an opportunity to monitor both morphology and contraction of a muscle non-invasively and demonstrates deep muscles without interaction from adjacent muscles.^[13,16] Evaluation of abdominal muscle thickness using ultrasonography has been shown to be highly reliable during different exercise positions in healthy adults.^[17-21]

In the present study, we hypothesized that thickness of TrA and IO would be greater, if abdominal contraction was performed with simultaneous contraction of GMax and LD (bridge with arm extension) than abdominal hollowing alone or abdominal contraction with simultaneous activation of only GMax (bridge) in healthy individuals. We, therefore, aimed to evaluate the changes in the thickness of abdominal muscles during activation of TLF through contracting GMax and LD muscles.

PATIENTS AND METHODS

This single-center, cross-sectional study was conducted at Koç University, Department of Physical Medicine and Rehabilitation between March 1st, 2019 and March 29th, 2019. A total of 30 healthy individuals (15 males, 15 females; mean age: 28.8±8.1 years; range, 21 to 52 years) among hospital staff were included. Inclusion criteria were age of >18 years and absence of back or abdominal problems. Those having recent lower back pain, history of trauma or surgery including back, abdominal or pelvic region, pregnancy congenital or acquired spinal disorders were excluded.

Demographic variables including age, sex, height, weight, and body mass index (BMI) were recorded. Thickness of TrA, IO, and external oblique (EO) muscles on the right side were evaluated at four positions: at rest, during abdominal hollowing, bridge, and bridge with isometric arm extension using the Esoate MyLab Class C ultrasound device equipped with 55 mm convex transducer (CA 541, B-mode, frequency 5 MHz).

The participants practiced the maneuvers before the measurements for correct performance. All measurements were performed with empty bladder and bowel. The participants were asked to wear comfortable clothes and lie supine with the soles touching the examination table, hips flexed 45°, knees flexed 90°, arms straight at the sides and spine placed in the middle. The transducer was placed over an intersection point of a horizontal line passing from the navel and a vertical line running through the anterior superior iliac spine. The transducer was moved laterally until EO, IO, and TrA muscles and anterior fascial insertion of TrA were accurately visualized. All images were recorded at the end of exhalation to minimize the effect of breathing. Subsequent images were obtained at rest, during abdominal hollowing, bridge, and bridge with isometric arm extension with 1-min rest between the maneuvers, with standardized instructions. For abdominal hollowing, the participants were asked to pull their navel in without any spinal or pelvic movement. In bridge exercise, they were asked to lift their pelvis, lumbar, and lower thoracic spine till scapula from the table, while contracting GMax simultaneously with abdominal hollowing. For bridge with arm extension, the participants were asked to press the table with their arms during bridge exercise (Figure 1). Thickness was measured using onscreen caliper by drawing a vertical line 20 mm lateral to the muscle-fascia junction of TrA as a reliable and valid method.^[22,23] The results were recorded in mm. Imaging and measurements were performed by a single experienced physiatrist.

Statistical analysis

The total sample size was calculated as 30 using the repeated measures analysis of variance (ANOVA) with 0.25 effect size, 0.05 type 1 error and 0.90 power for four measurements in one group, Statistical analysis was performed using the IBM SPSS for Windows version 24.0 software (IBM Corp., Armonk, NY, USA). Descriptive data were expressed in mean ± standard deviation (SD), median (interquartile range [IQR]) or number and frequency, where applicable. The Shapiro-Wilk test was used to check normal distribution of the variables. A one-way repeated measures ANOVA was used to evaluate the null hypothesis that there was no change in the participants' muscle thickness during rest, abdominal hollowing, and bridge with and without isometric arm extension for normal distributed variables. For multiple comparison, the *post-hoc* tests using the Bonferroni test were applied. The Friedman test and *post-hoc* analysis with the Wilcoxon signed-rank

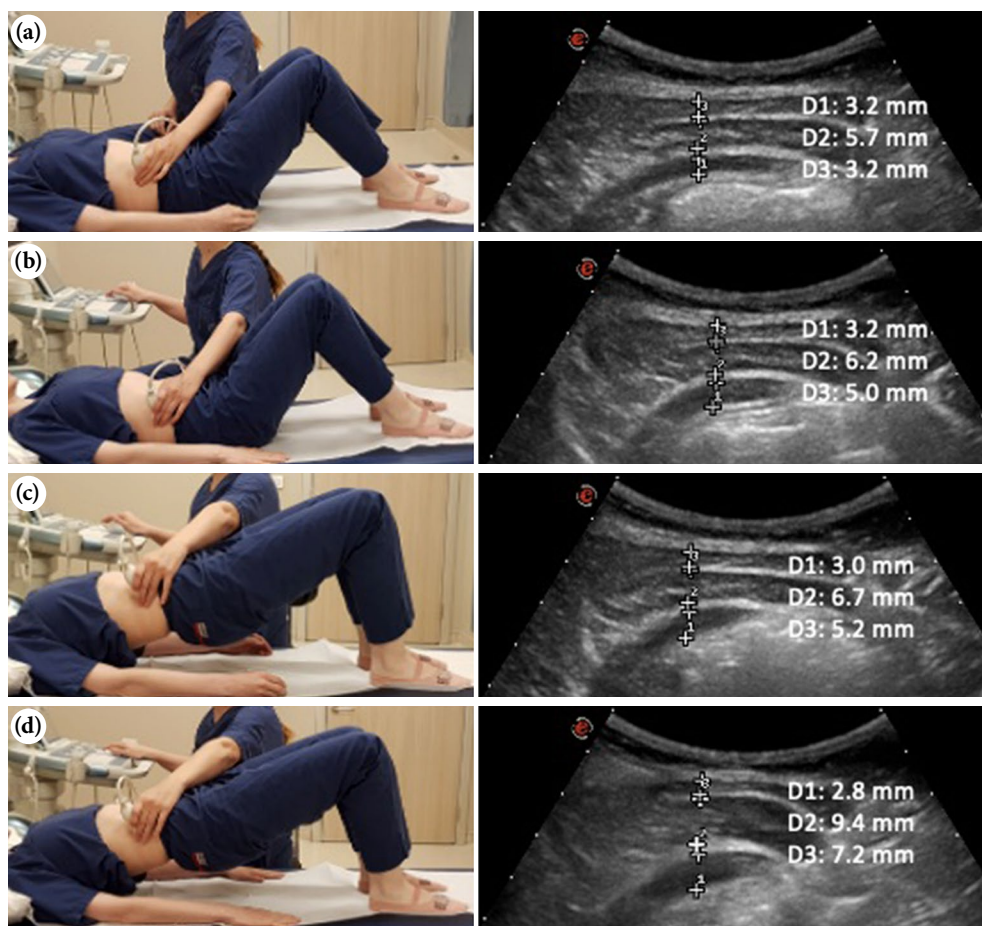


Figure 1. Positioning of the participant, placement of the transducer, and ultrasound images at rest during abdominal hollowing, bridge and bridge with isometric arm extension. (a) Rest. (b) Abdominal hollowing. (c) Bridge. (d) Bridge with isometric arm extension.

D1: External oblique thickness, D2: Internal oblique thickness, D3: Transversus abdominis thickness.

test were conducted for non-normally distributed variables (since the thickness of EO during abdominal hollowing and IO during bridge were not normally distributed changes in these muscle thicknesses were conducted non-parametrically). A p value of <0.05 was considered statistically significant.

RESULTS

The mean height, weight, and BMI of the participants were 170.2 ± 10.3 cm, 69.2 ± 14.1 kg, and 23.8 ± 4.1 kg/m², respectively.

There was a significant exercise position effect for TrA, that the mean muscle thickness statistically significantly differed between positions ($F(1.177, 51.331) = 26.828$, $p < 0.0005$). The TrA thickness was increased significantly during all exercise positions compared to rest (abdominal hollowing, bridge and bridge with arm extension, $p < 0.001$, $p < 0.001$, and

$p < 0.001$ respectively) and it was the highest during bridge with arm extension among all positions.

There was a significant difference in IO muscle thickness depending on the exercise position ($\chi^2(3) = 46.520$, $p < 0.001$). Median (IQR) muscle thickness for rest, abdominal hollowing, bridge and bridge with arm extension were 7 (5.85 to 9.45) mm, 8.75 (6.85 to 10.87) mm, 8.5 (6.12 to 11.5) mm and 11.1 (7.1 to 15.3) mm, respectively. The IO thickness was increased statistically significant during all exercise positions compared to rest (abdominal hollowing, bridge and bridge with arm extension, $Z = -4.023$, $p < 0.001$, $Z = -3.542$, $p < 0.001$ and $Z = -4.742$, $p < 0.001$, respectively) and it was the highest during bridge with arm extension among all positions.

There was a significant difference in the EO muscle thickness depending on the exercise position ($\chi^2(3) = 41.156$, $p < 0.001$). Median (IQR)

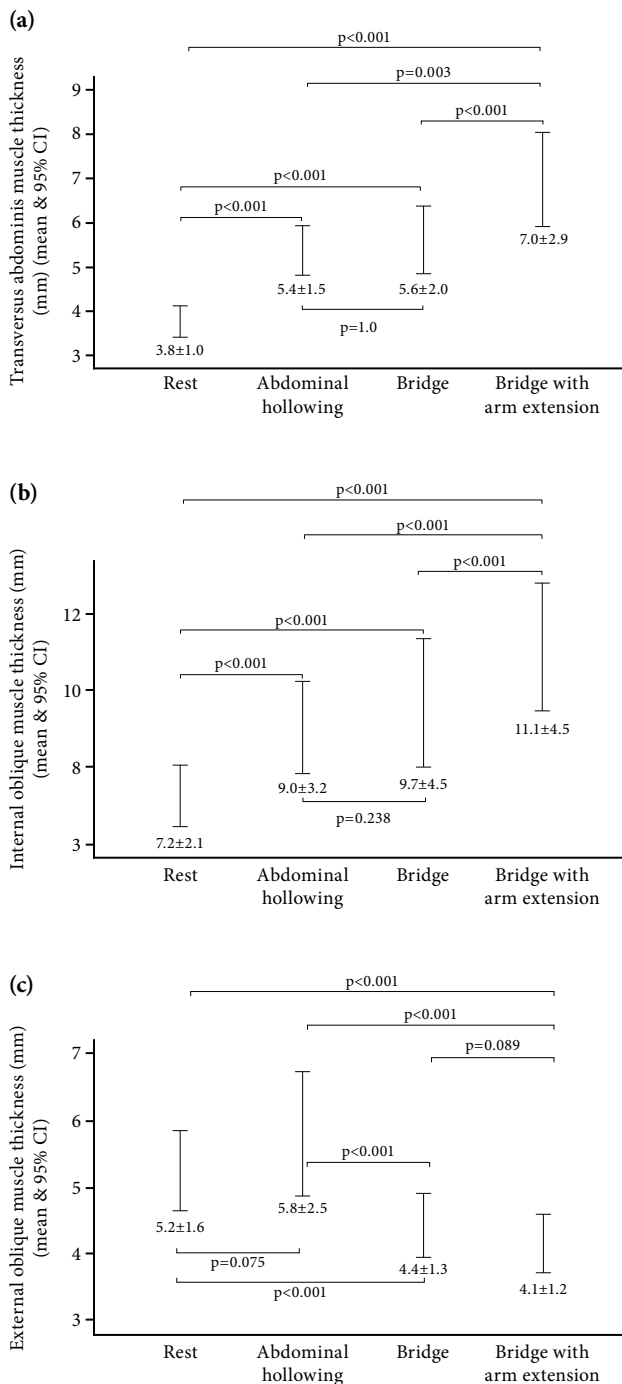


Figure 2. Mean±SD values for ultrasonographic thickness measurements of transversus abdominis (a), internal oblique and (b) external oblique (c) muscles at rest and during maneuvers, and p values conducted with *post-hoc* analysis.

CI: Confidence interval; SD: Standard deviation.

muscle thickness for rest, abdominal hollowing, bridge and bridge with arm extension were 4.8 (4.15 to 6.25) mm, 5.2 (4.35 to 6.9) mm, 4.2 (3.7 to 5.25) mm and 4 (3.4 to 4.75) mm, respectively.

The EO thickness was reduced significantly during bridge and bridge with arm extension compared to rest ($Z=-4.122$, $p<0.001$ and $Z=-4.382$, $p<0.001$), and in bridge with arm extension, compared to rest and abdominal hollowing ($Z=-4.382$, $p<0.001$ and $Z=-4.523$, $p<0.001$, respectively).

The mean thickness measurements of abdominal muscles at rest and during maneuvers are demonstrated in Figure 2. The thicknesses of TrA and IO muscles did not significantly differ between abdominal hollowing and bridge. During these two exercises, thicknesses were higher than rest and lower than bridge with arm extension. There was no significant difference in EO thickness between rest and abdominal hollowing. Thickness of EO during bridge was lower than rest and abdominal hollowing and similar to bridge with arm extension.

DISCUSSION

In this study, the changes in the thickness of abdominal muscles at rest and during abdominal hollowing, bridge, and bridge with arm extension were evaluated. Ultrasonographic thickness of IO and TrA were the lowest at rest and greatest during bridge with isometric arm extension, compared to other positions. Contraction of GMax and LD in bridge with isometric arm extension increased the thickness of IO and TrA.

Activation of TrA and IO is an initial step in core stabilization. The TrA originates from the middle layer of TLF, while the IO originates from iliac crest, iliac fibers of LD, and lateral raphe.^[9] The TrA fibers run horizontally like a belt around the abdomen causing lateral tension^[9] and can be activated by abdominal hollowing.^[4] In this study, the thickness of TrA and IO increased with abdominal hollowing compared to rest, as expected. Middle layer of TLF arises from lumbar transverse processes and posterior layer arises from lumbar spinous process wrapping the erector spina. All layers fuse at lateral raphe and give rise to TrA and partially IO.^[9] During abdominal hollowing, contraction of TrA and IO stretches TLF and, then, activates erector spina generating segmental stabilization. Therefore, abdominal hollowing is a widely used exercise in the spinal rehabilitation.^[15,24,25]

Bridge exercise which requires activation of GMax can increase the thickness of TrA and IO. This action is suggested to be achieved through myofascial force transmission between TLF and contralateral GMax as demonstrated in cadaveric models.^[26,27] Due to the connection of GMax to TLF and iliotibial tract, it

assists load transfer through lumbar spine, pelvis, and contralateral lower limb.^[28,29] In the present study, the thickness of TrA and IO was significantly greater in bridge than rest, but similar to abdominal hollowing. Co-activation of GMax in bridge increased the thickness of TrA and IO compared to abdominal hollowing; although it did not reach statistical significance. It is suggested that bridge does not sufficiently activate TLF and its connection to back functional chain.

Lattissimus dorsi attaches proximally to intertubercular groove, covers the back of the torso, and attaches to the T7 - sacral spinous processes, iliac crest, and lateral raphe of TLF,^[9,30] continues with the aponeurosis of contralateral GMax.^[26,27] The LD adducts and extends the shoulder, extends and laterally flexes the back. Aponeurosis of LD forms the superficial lamina of the posterior layer of TLF and fuses with the middle layer of TLF in the lateral raphe bracing the low back region.^[9] Cadaveric studies demonstrated the displacement of TLF by direct traction on the LD or GMax, suggesting a myofascial force transmission.^[26,27] An *in vivo* study demonstrated that passive and active LD tensioning caused lateral rotation of the hip which supports this connection.^[11] An electromyographic study exhibited that activity of LD was the highest during hip extension.^[12] The present study demonstrated that the thickness of TrA and IO during bridge with arm extension was significantly greater than abdominal hollowing or bridge. Addition of LD contraction to abdominal and GMax contraction is suggested to enhance abdominal muscle function through TLF.

Regarding EO, even three measurements were not enough for reliability^[19] and EO muscle thickness did not change with contraction, despite the change in electromyographic activity.^[13] These findings are in accordance with our study that EO thickness did not change with maneuvers.

To the best of our knowledge, this is the first study that demonstrate TrA and IO muscle thickness change during LD contraction with bridge using ultrasound. Ultrasonography also may increase the quality of training with providing feedback about muscle contraction for individuals that have difficulty performing the exercise properly.^[16]

In conclusion, this study demonstrates that co-activation of LD and GMax during abdominal muscle contraction increases the thickness of IO and TA muscles greater than abdominal muscle contraction alone or with activation of GMax. These findings suggest that addition of LD contraction

enhances abdominal muscle function through TLF and myofascial muscle chains.

Ethics Committee Approval: The study protocol was approved by the Medical Ethics Committee of Koç University (2019.100.IRB1.012). The study was conducted in accordance with the principles of the Declaration of Helsinki. The study was registered at ClinicalTrials.gov (NCT04113642).

Patient Consent for Publication: A written informed consent was obtained from each patient.

Data Sharing Statement: The data that support the findings of this study are available from the corresponding author upon reasonable request.

Author Contributions: Design, data collection, writing of manuscript; Z.T.; Study design, statistical analysis, manuscript writing; Ö.Ö.T.

Conflict of Interest: The authors declared no conflicts of interest with respect to the authorship and/or publication of this article.

Funding: The authors received no financial support for the research and/or authorship of this article.

REFERENCES

1. Panjabi MM. Clinical spinal instability and low back pain. *J Electromyogr Kinesiol* 2003;13:371-9.
2. Ungaro A. *Pilates: Body in Motion*. London: Dorling Kindersley; 2002.
3. Key J. 'The core': Understanding it, and retraining its dysfunction. *J Bodyw Mov Ther* 2013;17:541-59.
4. Akuthota V, Ferreiro A, Moore T, Fredericson M. Core stability exercise principles. *Curr Sports Med Rep* 2008;7:39-44.
5. Panjabi MM. The stabilizing system of the spine. Part II. Neutral zone and instability hypothesis. *J Spinal Disord* 1992;5:390-6.
6. Panjabi M, Abumi K, Duranceau J, Oxland T. Spinal stability and intersegmental muscle forces. A biomechanical model. *Spine (Phila Pa 1976)* 1989;14:194-200.
7. Schleip R, Müller DG. Training principles for fascial connective tissues: Scientific foundation and suggested practical applications. *J Bodyw Mov Ther* 2013;17:103-15.
8. Willard FH, Vleeming A, Schuenke MD, Danneels L, Schleip R. The thoracolumbar fascia: Anatomy, function and clinical considerations. *J Anat* 2012;221:507-36.
9. Bogduk N, Macintosh JE. The applied anatomy of the thoracolumbar fascia. *Spine (Phila Pa 1976)* 1984;9:164-70.
10. Wilke J, Krause F, Vogt L, Banzer W. What is evidence-based about myofascial chains: A systematic review. *Arch Phys Med Rehabil* 2016;97:454-61.
11. Carvalhais VO, Ocarino Jde M, Araújo VL, Souza TR, Silva PL, Fonseca ST. Myofascial force transmission between the latissimus dorsi and gluteus maximus muscles: An *in vivo* experiment. *J Biomech* 2013;46:1003-7.
12. Escamilla RF, Lewis C, Bell D, Bramblet G, Daffron J, Lambert S, et al. Core muscle activation during Swiss ball and traditional abdominal exercises. *J Orthop Sports Phys Ther* 2010;40:265-76.

13. Hodges PW, Pengel LH, Herbert RD, Gandevia SC. Measurement of muscle contraction with ultrasound imaging. *Muscle Nerve* 2003;27:682-92.
14. Ferreira PH, Ferreira ML, Nascimento DP, Pinto RZ, Franco MR, Hodges PW. Discriminative and reliability analyses of ultrasound measurement of abdominal muscles recruitment. *Man Ther* 2011;16:463-9.
15. Chanthapetch P, Kanlayanaphotporn R, Gaogasigam C, Chiradejnant A. Abdominal muscle activity during abdominal hollowing in four starting positions. *Man Ther* 2009;14:642-6.
16. Hodges PW. Ultrasound imaging in rehabilitation: Just a fad? *J Orthop Sports Phys Ther* 2005;35:333-7.
17. Costa LO, Maher CG, Latimer J, Smeets RJ. Reproducibility of rehabilitative ultrasound imaging for the measurement of abdominal muscle activity: A systematic review. *Phys Ther* 2009;89:756-69.
18. Linek P, Saulicz E, Wolny T, Myśliwiec A. Intra-rater reliability of B-mode ultrasound imaging of the abdominal muscles in healthy adolescents during the active straight leg raise test. *PM R* 2015;7:53-9.
19. Linek P, Saulicz E, Wolny T, Myśliwiec A. Reliability of B-mode sonography of the abdominal muscles in healthy adolescents in different body positions. *J Ultrasound Med* 2014;33:1049-56.
20. Gibbon KC, Debuse D, Hibbs A, Caplan N. Reliability and precision of sonography of the Lumbar Multifidus and Transversus Abdominis during dynamic activities. *J Ultrasound Med* 2017;36:571-81.
21. Mangum LC, Sutherlin MA, Saliba SA, Hart JM. Reliability of ultrasound imaging measures of transverse abdominis and lumbar multifidus in various positions. *PM R* 2016;8:340-7.
22. Gnat R, Saulicz E, Miądowicz B. Reliability of real-time ultrasound measurement of transversus abdominis thickness in healthy trained subjects. *Eur Spine J* 2012;21:1508-15.
23. Kim JS, Seok CH, Jeon HS. Abdominal draw-in maneuver combined with simulated weight bearing increases transversus abdominis and internal oblique thickness. *Physiother Theory Pract* 2017;33:954-8.
24. Teyhen DS, Miltenberger CE, Deiters HM, Del Toro YM, Pulliam JN, Childs JD, et al. The use of ultrasound imaging of the abdominal drawing-in maneuver in subjects with low back pain. *J Orthop Sports Phys Ther* 2005;35:346-55.
25. Panjabi MM. The stabilizing system of the spine. Part I. Function, dysfunction, adaptation, and enhancement. *J Spinal Disord* 1992;5:383-9.
26. Barker PJ, Briggs CA, Bogeski G. Tensile transmission across the lumbar fasciae in unembalmed cadavers: Effects of tension to various muscular attachments. *Spine (Phila Pa 1976)* 2004;29:129-38.
27. Vleeming A, Pool-Goudzwaard AL, Stoeckart R, van Wingerden JP, Snijders CJ. The posterior layer of the thoracolumbar fascia. Its function in load transfer from spine to legs. *Spine (Phila Pa 1976)* 1995;20:753-8.
28. Barker PJ, Hapuarachchi KS, Ross JA, Sambaiew E, Ranger TA, Briggs CA. Anatomy and biomechanics of gluteus maximus and the thoracolumbar fascia at the sacroiliac joint. *Clin Anat* 2014;27:234-40.
29. Stecco A, Gilliar W, Hill R, Fullerton B, Stecco C. The anatomical and functional relation between gluteus maximus and fascia lata. *J Bodyw Mov Ther* 2013;17:512-7.
30. Bogduk N, Johnson G, Spalding D. The morphology and biomechanics of latissimus dorsi. *Clin Biomech (Bristol, Avon)* 1998;13:377-85.