

Case Report

Orthostatic tremor after knee contusion without head trauma: A rare case report

San-Ha Kim¹, Jae-Young Han², Min-Keun Song², In Sung Choi¹, Hyeng-Kyu Park²

¹Department of Physical & Rehabilitation Medicine, Chonnam National University Hospital, Gwangju City, Republic of Korea

²Department of Physical & Rehabilitation Medicine, Regional Cardiocerebrovascular Center, Center for Aging and Geriatrics, Chonnam National University Medical School & Hospital, Gwangju, Republic of Korea

Received: April 01, 2021 Accepted: July 08, 2021 Published online: September 14, 2022

ABSTRACT

Orthostatic tremor (OT) is an uncommon progressive movement disorder that involves a leg tremor when standing or weight bearing. Additionally, OT can accompany other medical or neurodegenerative disorders. In this article, we report an unusual case of OT after trauma in an 18-year-old male patient whose symptoms of OT have been resolved after a multimodal therapeutic approach, including botulinum toxin injection. Surface electromyography, including a tremor recording, was used for the diagnosis of OT. The patient completely recovered after the rehabilitation. A comprehensive rehabilitative treatment is required in the management of OT as the patient's quality of life is greatly affected.

Keywords: Botulinum toxin, orthostatic tremor, surface electromyography, trauma.

In 1970, orthostatic tremor (OT) was first reported and characterized as a lower limb tremor when standing or weight bearing that disappeared while seated or lying.^[1,2] Orthostatic tremor is rare and thought to be a progressive disorder.^[2] Most cases develop during the sixth decade of life, with a female preponderance.^[1] Orthostatic tremor may be primary (idiopathic) or associated with several neurological and medical conditions, including dementia, spinocerebellar ataxia, Parkinson's disease, parkinsonism, restless legs syndrome, and progressive supranuclear palsy.^[1] A family history of OT was also reported.^[2]

The pathophysiology of OT is thought to involve the posterior fossa oscillator, pons, and cerebellum.^[3,4] Katzenschlager et al.^[5] reported that

OT is associated with a presynaptic dopaminergic deficit, while another study stated that OT is not affected by the dopaminergic pathway.^[6] Moreover, another article suggests that OT can be caused by abnormal proprioception in peripheral nervous system.^[7] The pathophysiology of OT remains unclear.

Orthostatic tremor is diagnosed by surface electromyography (EMG), including a tremor recording, and the clinical presentation. Orthostatic tremors can be subdivided into classical OT and slow OT based on the tremor frequency.^[2] The treatment of OT includes medical treatment, botulinum toxin injection, and deep brain stimulation.^[3] However, the empirically used pharmacological agents and other treatments often yield insufficient benefits.^[8]

Corresponding author: Hyeng-Kyu Park, MD, PhD. Department of Physical & Rehabilitation Medicine, Chonnam National University Hospital, #42, Jebong-Ro, Dong-Gu, Gwangju, 61469, Republic of Korea.

E-mail: phk1118@naver.com

Cite this article as:

Kim SH, Han JY, Song MK, Choi IS, Park HK. Orthostatic tremor after knee contusion without head trauma: A rare case report. Turk J Phys Med Rehab 2023;69(1):111-115. doi: 10.5606/tftrd.2023.8718

©2023 All right reserved by the Turkish Society of Physical Medicine and Rehabilitation

This is an open access article under the terms of the Creative Commons Attribution-NonCommercial License, which permits use, distribution and reproduction in any medium, provided the original work is properly cited and is not used for commercial purposes (<http://creativecommons.org/licenses/by-nc/4.0/>).



Most cases of OT are associated with neurodegenerative disorders.^[3,4] Otherwise, OT is exceedingly rare, particularly after trauma. Herein, we report the diagnosis and treatment of OT that developed after trauma.

CASE REPORT

An 18-year-old man presented to our rehabilitation center due to a left leg tremor when standing or walking, which began after a knee contusion caused by a motorcycle mishap that had occurred nine months earlier. The patient did not have any history of hospital admission and had no disease requiring routine follow-up. There was no specific family history or social history to report. The patient described only a slight knee contusion at the time of the accident and no splash injury, other external wounds, or fracture. Interestingly, neither direct contusion of the head and spine nor change of consciousness, including memory loss, was shown after the incident, and the patient was treated conservatively with a muscle relaxant and nonsteroidal anti-inflammatory drugs at another hospital. Symptoms first appeared soon after the accident and had persisted for nine months, until the first visit to hospital. The patient was admitted to our Department of Rehabilitation Medicine for further evaluation and management of this symptom. At that time, his consciousness was normal, and there was no difference compared to before the accident.

At the first visit to our department, the patient's left leg strength was 4/5 on manual muscle testing. There was no spasticity and the deep tendon reflexes were normal. The patient showed decreased balance and required crutches to walk due to the left lower leg tremor. The left lower leg tremor occurred when there was a weight load while standing or walking but not sitting or lying. Cerebellar function tests were normal. There was no obvious abnormality in the brain magnetic resonance imaging (MRI). Thoracic spine MRI was normal, and lumbar spine MRI revealed only spondylosis at the L5 level with no spinal cord abnormalities. The patient was initially treated with 10 mg of oral baclofen daily. However, no effect was observed with baclofen.

The patient was also referred to the department of neurology. Several laboratory tests were performed, and electrodiagnostic studies, including surface EMG, were recommended. Laboratory tests, comprising a complete blood cell count, thyroid function test, liver function test, electrolyte level, and serum copper and ceruloplasmin level, were within normal range.

Electrodiagnostic study was done one week after the initial visit. The nerve conduction study and needle EMG were normal. Surface EMG of the left anterior and posterior leg muscles showed a 5-6 Hz tremor while standing, confirming the diagnosis of slow OT (Figure 1).

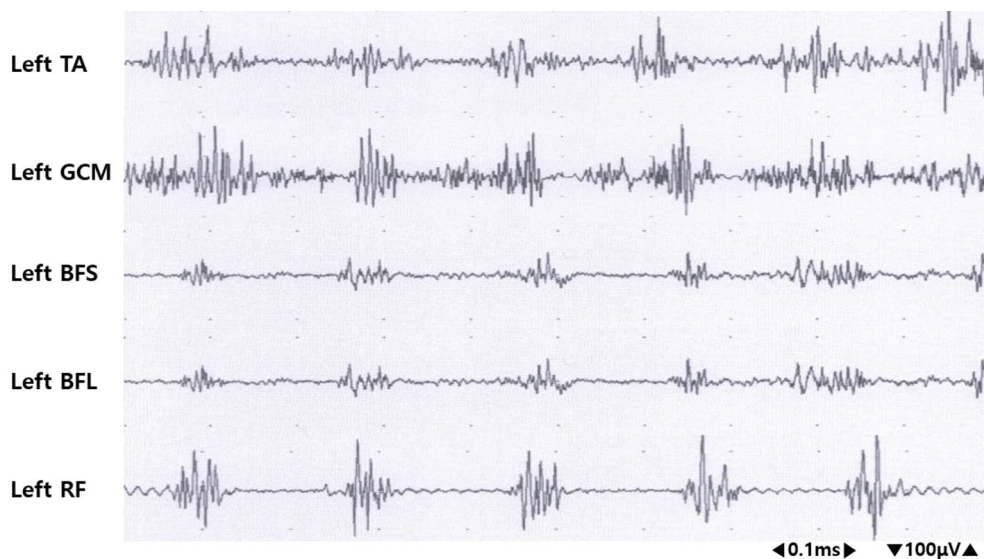


Figure 1. Surface electromyography of the left leg muscles show discharges at a frequency of 5-6 Hz while standing (sensitivity 100 μ V/div, sweep speed 0.1 s/div).

TA: Tibialis anterior; GCM: Medial head of gastrocnemius; BFS: Short head of biceps femoris; BFL: Long head of biceps femoris; RF: Rectus femoris.

TABLE 1
Functional parameters before and after therapeutic management

	1 st assessment (Before intervention)		*2 nd assessment (After intervention)	
	U/E(N/N)	L/E(N/G)	U/E(N/N)	L/E(N/G)
MMT (right/left)				
Berg balance scale	44		51	
Timed up and go test (sec)	13.49		9.94	
10-meter walking test (m/sec)				
Comfortable	0.87		0.67	
Fast	1.13		0.89	

MMT: Manual muscle test; U/E: Upper extremities; L/E: Lower extremities; N: Normal; G: Good; * Six months after the 1st assessment, which is three months after the botulinum toxin injection.

Two weeks after the initial visit, a tibial nerve block below the knee was performed using 2 mL of 1% lidocaine, and temporary improvement was observed, but the symptom remained. Since there was a mild improvement, additional sciatic nerve blocks using 2 mL 1% lidocaine were done. As with previous injections, symptoms were temporarily relieved, and the effect diminished after a duration. Two months after the initial visit, a caudal block was performed using 10 mL of 1% lidocaine with no effect. Three months after the initial visit, 100 U of botulinum toxin was medially and laterally injected into the left gastrocnemius muscle. Two months after the botulinum toxin injection, we replaced the baclofen with propranolol 20 mg daily.

The tremor resolved mainly after botulinum toxin injection on the left gastrocnemius muscle. The tremor gradually improved one week after the botulinum toxin injection, and three months after the injection, clinical improvement was seen in the Berg Balance Scale, Timed Up and Go test, and 10-m walking test compared with baseline (Table 1). The Berg Balance Scale is a 14-item test scored from 0 (impaired) to 4 (normal) for each item that can assess static and dynamic balance not only in general conditions but also in orthostatic tremor patients.^[9] Eleven months after the initial visit, the tremor had disappeared, and all medications were terminated. A follow-up electrodiagnostic study was performed with no electrodiagnostic abnormality. At the two-year follow-up, the patient remained asymptomatic.

DISCUSSION

Despite many reports on OT, the mechanism is still unclear. Fung et al.^[7] reported that OT is caused by a tremulous disruption of proprioceptive

afferent activity from the legs. It causes cocontraction of the leg muscles to increase stability, and the increased activity of the tremor-associated muscles results in proprioceptive input, as in a vicious cycle.^[7] Orthostatic tremors may be present with degenerative diseases associated with dopamine, cerebellar disease, and other degenerative diseases.^[5] However, our patient was a young adult with no neurological symptoms except OT, which could not be explained by these pathways. Adebayo et al.^[10] reported a case of aggravation of OT after total hip replacement surgery, and interpreted that the worsening may be due to damage of proprioceptive fibers during and after surgery. Similarly, the knee trauma in our case might have activated another pathway, such as a proprioceptive afferent pathway.

According to the tremor frequency, OTs can be subdivided into classical OT (13-18 Hz) and slow OT (<13 Hz).^[3,11] In a single-photon emission computed tomography imaging study of parkinsonism, Hassan and Caviness^[11] reported that slow OT was more pronounced ipsilateral to the brain lesion. The cerebellum, pons, medulla, and upper spinal cord have been hypothesized as potential lesion sites based on symptomatic cases of slow OT. In our case, however, the tremor was present in one leg only, with a slow OT of 5-6 Hz. There was no abnormality related to the tremor on brain or spine MRI, and no symptoms suggested other diseases known to cause OT.

Orthostatic tremor is a progressive neurodegenerative disorder, and patients may develop additional neurological signs in the long term.^[4] Orthostatic tremors may require long-term treatment.

Pharmacological agents such as clonazepam and gabapentin can be used in OT; however, the definitive benefit is still in question.^[8] Additionally, most studies about the effect of pharmacological

agents were mainly targeted with primary OT or OT with other neurological symptoms, particularly in the aged patients. Considering the development of OT and the onset age of our patient, we adopted other treatment options. In our case, both tibial and sciatic nerve blocks using lidocaine were temporarily effective, yet the caudal epidural block was not significantly effective. The physiological mechanism of the improvement is still unclear but may be due to the correction of abnormal proprioceptive input. It is known that peripheral nerve blocks such as sciatic nerve, tibial nerve, and caudal epidural block can influence the sensory afferent pathways, including nociceptive pathways and proprioceptive pathways.^[12]

The OT in our case resolved mainly after botulinum toxin injection in the gastrocnemius muscle. Gonzalez-Alegre et al.^[13] reported that botulinum toxin injection relieved a high-frequency jaw tremor electrophysiologically similar to OT. They postulated that the botulinum toxin preponderantly affected the intrafusal fibers since there was no marked motor weakness. Another study revealed that botulinum toxin injection also affects sensory afferent fibers, particularly in nociceptive pathways.^[14] Furthermore, Bertram et al.^[15] reported that the effectiveness of botulinum toxin injection in OT may not be significant. However, they stated that the dose or injection strategies might have been insufficient to interfere with proprioceptive pathways, and the author argued that the potential benefit of botulinum toxin injection should not be excluded. Similarly, in our case, the OT improved after botulinum toxin injection without motor weakness. The botulinum toxin injection may have affected the intrafusal muscle fibers associated with the proprioceptive afferent pathway. As there is no recommended regimen using botulinum toxin injection in OT, further studies are needed to set up the clinical efficacy and optimal dose of botulinum toxin in OT.

Our patient had discomfort in daily living due to the decreased balance. After the resolution of OT, the parameters associated with balance and gait status were enhanced and the discomfort in daily living also improved. Due to its rareness, the treatment of OT is not well established. In addition to current therapeutic strategies with pharmacological agents and surgical treatments like deep brain stimulation, multimodal therapeutic options can be considered to treat OT and further investigations are required to understand the pathophysiology, and treatment of OT.

In conclusion, the OT of unknown origin that developed after trauma in our patient was completely treated after multiple therapeutic approaches. As OT can result in functional decline of daily living, comprehensive rehabilitative treatment options should be considered in its management, and further studies are required to understand the pathophysiology and treatment of OT.

Ethics Committee Approval: This study was approved by the Chonnam National University Hospital Institutional Review Board (CNUH-EXP-2018-14).

Patient Consent for Publication: Written informed consent for the publication of this case report and any accompanying images were obtained from the patient himself.

Data Sharing Statement: The data that support the findings of this study are available from the corresponding author upon reasonable request.

Author Contributions: Concept: J.H., H.P.; Design: J.H., H.P.; Supervision: S.K., J.H., M.S., I.S.C., H.P.; Resources: M.S.; Materials: S.K., H.P.; Data collection and/or processing: S.K., H.P.; Analysis and/or interpretation: M.S., I.S.C.; Literature search: S.K., I.S.C.; Writing manuscript: S.K., J.H., H.P.; Critical review: S.K., J.H., M.S., I.S.C., H.P.

Conflict of Interest: The authors declared no conflicts of interest with respect to the authorship and/or publication of this article.

Funding: Supported by a grant (BCRI 21054) Chonnam National University Hospital.

REFERENCES

- Gerschlagel W, Brown P. Orthostatic tremor - a review. *Handb Clin Neurol* 2011;100:457-62.
- Yaltho TC, Ondo WG. Orthostatic tremor: A review of 45 cases. *Parkinsonism Relat Disord* 2014;20:723-5.
- Hassan A, van Gerpen JA. Orthostatic tremor and orthostatic myoclonus: Weight-bearing hyperkinetic disorders: A systematic review, new insights, and unresolved questions. *Tremor Other Hyperkinet Mov (N Y)* 2016;6:417.
- Lenka A, Pal PK, Bhatti DE, Louis ED. Pathogenesis of primary orthostatic tremor: Current concepts and controversies. *Tremor Other Hyperkinet Mov (N Y)* 2017;7:513.
- Katzenschlagel R, Costa D, Gerschlagel W, O'Sullivan J, Zijlmans J, Gacinovic S, et al. [123I]-FP-CIT-SPECT demonstrates dopaminergic deficit in orthostatic tremor. *Ann Neurol* 2003;53:489-96.
- Trocello JM, Zanotti-Fregonara P, Roze E, Apartis E, Legrand AP, Habert MO, et al. Dopaminergic deficit is not the rule in orthostatic tremor. *Mov Disord* 2008;23:1733-8.
- Fung VS, Sauner D, Day BL. A dissociation between subjective and objective unsteadiness in primary orthostatic tremor. *Brain* 2001;124:322-30.

8. Benito-León J, Domingo-Santos Á. Orthostatic tremor: An update on a rare entity. *Tremor Other Hyperkinet Mov (N Y)* 2016;6:411.
9. Bhatti D, Thompson R, Xia Y, Hellman A, Schmaderer L, Suing K, et al. Comprehensive, blinded assessment of balance in orthostatic tremor. *Parkinsonism Relat Disord* 2018;47:22-5.
10. Adebayo PB, Gunduz A, Kiziltan ME, Kiziltan G. Upper limbs spread of orthostatic tremor following hip replacement surgery. *Neurol India* 2014;62:462-3.
11. Hassan A, Caviness J. Slow orthostatic tremor: Review of the current evidence. *Tremor Other Hyperkinet Mov (N Y)* 2019;9.
12. Paqueron X, Gentili ME, Willer JC, Coriat P, Riou B. Time sequence of sensory changes after upper extremity block: Swelling sensation is an early and accurate predictor of success. *Anesthesiology* 2004;101:162-8.
13. Gonzalez-Alegre P, Kelkar P, Rodnitzky RL. Isolated high-frequency jaw tremor relieved by botulinum toxin injections. *Mov Disord* 2006;21:1049-50.
14. Kumar R, Dhaliwal HP, Kukreja RV, Singh BR. The botulinum toxin as a therapeutic agent: Molecular structure and mechanism of action in motor and sensory systems. *Semin Neurol* 2016;36:10-9.
15. Bertram K, Sirisena D, Cowey M, Hill A, Williams DR. Safety and efficacy of botulinum toxin in primary orthostatic tremor. *J Clin Neurosci* 2013;20:1503-5.