



Lupus-like Syndrome Induced by Anti-tumor Necrosis Factor Treatment

İsmail CÖMERTOĞLU, Memet KURT, Ayşe PEYMAN YALÇIN

Department of Physical Medicine and Rehabilitation, Ankara University Faculty of Medicine, Ankara, Turkey

Abstract

Anti-tumor necrosis factor (TNF) agents have been successfully used in the treatment of inflammatory rheumatic diseases for more than 10 years. Although it is rare disease, a lupus-like syndrome may develop and life-threatening visceral involvement may be observed during treatment with anti-TNF drugs. Herein, we present a patient with ankylosing spondylitis who developed a lupus-like syndrome while undergoing treatment with infliximab.

Keywords: Infliximab, ankylosing spondylitis, lupus-like syndrome

Introduction

Drug-induced lupus (DIL) may develop during treatment with tumor necrosis factor (TNF)-alpha antagonists, which have been used to treat autoimmune, inflammatory, and rheumatic diseases for more than 10 years. To date, cases of DIL have been reported in association with infliximab, etanercept, adalimumab, and certolizumab pegol therapies (1). It is a syndrome with no standardized diagnostic criteria, but it is diagnosed in a patients with no history of DIL after at least 1 month of exposure to the causative agent and the associated symptoms may resolve when the drug administration is stopped (2). Although ANA and anti-dsDNA positivity are frequent with the use of TNF-alpha antagonists, the occurrence of DIL is rare (3,4). The clinical manifestations of DIL may be extremely variable and include the presence of arthralgia, myalgia, skin eruptions, cytopenia, fever, serositis, and ANA as well as anti-dsDNA positivity (5).

In this article, we present a patient with ankylosing spondylitis (AS) who developed DIL after 1 year of treatment with infliximab.

Case Report

A 37-year-old female patient with a diagnosis of AS since 1999 was admitted for increasing low back pain radiating to the left hip and low back stiffness with motion. The HLA-B27 test was positive; bilateral sacroiliitis was found on the plain radiographs (Figure 1). She was undergoing treatment with sulfasalazine (2 g/day) and indomethacin (200 mg/day).

In November 2009, 5 mg/kg of infliximab was administered to the patient because of increased complaints of pain, stiffness with motion, and a Bath Ankylosing Spondylitis Disease Activity Index (BASDAI) score of more than 5.1. The erythrocyte sedimentation rate (ESR) and C-reactive protein (CRP) levels were

Address for Correspondence: İsmail Cömertoğlu, MD, E-mail: drcomertoglu@yahoo.com

Received: July 2013 Accepted: July 2014

©Copyright 2015 by Turkish Society of Physical Medicine and Rehabilitation - Available online at www.ftdergisi.com

Cite this article as:

Cömertoğlu İ, Kurt M, Peyman Yalçın A. Lupus-like Syndrome Induced by Anti-tumor Necrosis Factor Treatment. Turk J Phys Med Rehab 2015;61:371-4.

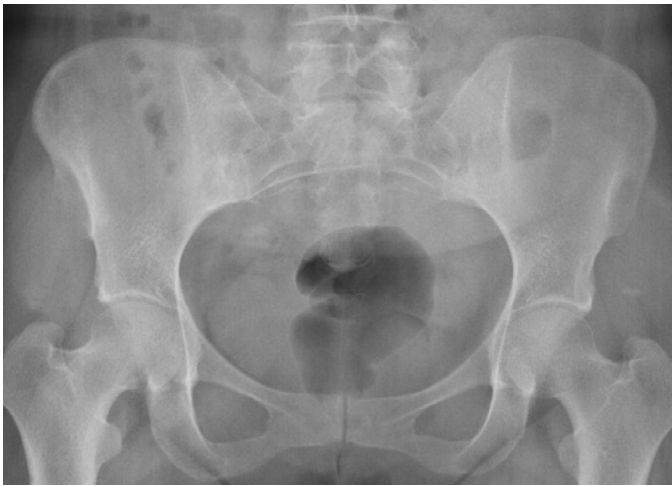

Figure 1. Bilateral sacroiliitis

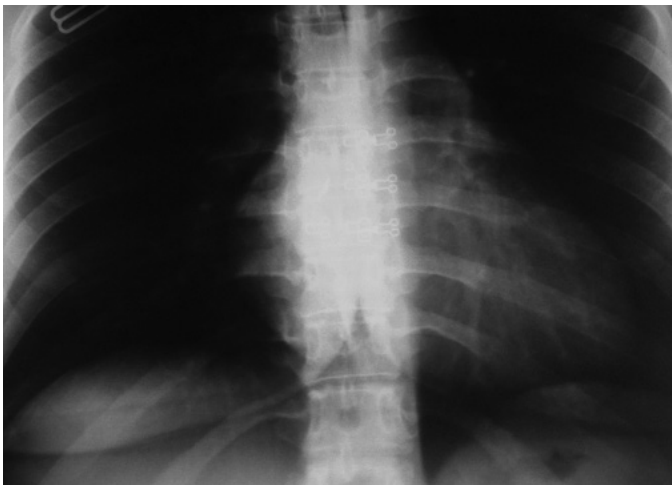

Figure 2. Increased cardiothoracic ratio, AP view. AP: antero-posterior

44 mm/h (0–20 mm/h) and 54.7 mg/L (0–3 mg/L), respectively. With this treatment, the patient's symptoms improved; ESR level decreased to 18 mm/h, CRP level decreased to 9.31 mg/L, and BASDAI score decreased to 2.

In March 2011, the patient visited our rheumatology outpatient clinic with the complaint of bilateral arthritis of the ankles. In her physical examination, her respiratory sounds were decreased over the left basal segment of the lung. Rales, dullness, and bilateral pretibial edema were also present. On the locomotor system examination, her neck flexion was limited and painful. The distance from the chin to the sternum was up to 3 cm. Low back extension was limited, modified Schober was 2 cm, and chest expansion was 3 cm. The range of motion in her hips were limited and painful. Her bilateral ankle joints were inflamed and BASDAI score was 5.2. The laboratory findings were as follows: hemoglobin, 10.8 g/dL; ESR, 77 mm/h; and CRP, 61 mg/L. The immunoglobulin and complement levels were normal and immunological markers; ANA (+++), anti-dsDNA (-), RF (-), ENA (-), anti-histone antibody (-). Urinalysis revealed proteinuria of

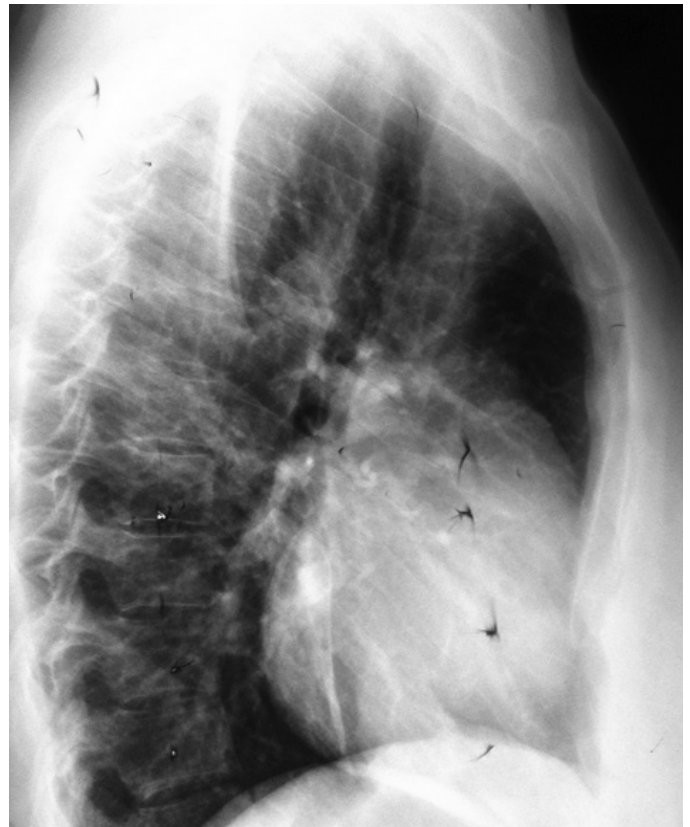


Figure 3. Pericardial effusion, lateral view

300 mg/day; cryoglobulinemia was not present. After 1 month, a chest X-ray was performed for the patient because she experienced shortness of breath and chest pain. Because the presence of pleural effusion was indicative of DIL, infliximab treatment was stopped. The patient was subsequently hospitalized for further investigation and treatment.

The Department of Hematology first evaluated the patient, and she was diagnosed with anemia of chronic disease. The patient complained of shortness of breath and chest pain and was referred to the Department of Respiratory Medicine. X-ray analysis revealed that the left sinus was closed, and that linear atelectasis was present. Computed tomography of the thorax showed peribronchial thickening of the left lobe and infiltration with a honeycomb appearance. No evidence was found with regard to tuberculosis or pulmonary emboli; therefore, antibiotic treatment was commenced (moxifloxacin TB, 400 mg/day) for prophylaxis. In control chest X-ray (after 1 week) analysis, pleural effusion was decreased; however, the cardiothoracic ratio was also increased (Figure 2,3). Subsequently, she was referred to the Department of Cardiology. Echocardiography (ECHO) showed a pericardial effusion and right atrium collapse. Pericardiostomy was performed and approximately 200 mL of serous fluid was discharged; no pathogen was isolated from the fluid sample. The patient was then referred to the Department of Infectious Disease. Infectious etiologies such as viral markers [Cytomegalovirus (CMV), Epstein-barr virus (EBV) and human immune deficiency virus (HIV)], sputum acid-resistant bacilli (ARB), tu-

berculosis culture, Brucella, Chlamydia, and Mycoplasma were ruled out. Because the pericardial biopsy was consistent with fibrinous pericarditis, the patient was treated with 60 mg/day of oral prednisolone. The control ECHO was also normal.

The patient recovered, her symptoms resolved, her ESR and CRP levels returned to normal levels, and she was discharged after being administered with gradually decreasing doses of prednisolone. ANA became negative and it continued to remain negative during the follow-up examinations and x-ray analysis. Our patient continues to receive 200 mg/day of indomethacin and 2 g/day of sulfasalazine. Here, we report a case of DIL after obtaining informed consent from the patient for the publication of this report.

Discussion

Worldwide, DIL constitutes approximately 10% of the systemic lupus erythematosus (SLE) cases, with widely different incidences and prevalence rates (5,6). Although there is no specific diagnostic criteria for DIL, there are at least four important diagnostic criteria of the American College of Rheumatology for SLE, including drug exposure and regression of the symptoms after withdrawal of the drug administration (7). The pathophysiology of DIL remains unclear. As opposed to SLE, DIL is observed with an equal frequency in males and females and more commonly in the elderly (2). In patients with DIL, constitutional symptoms and musculoskeletal and mucocutaneous findings with autoantibody positivity are similar to those observed in patients with SLE (5). However, there are some differences such as higher frequency of mucocutaneous findings and visceral involvement but lower frequency of musculoskeletal findings in patients with DIL (7).

TNF-alpha plays an important role in the pathogenesis of autoimmune and rheumatic diseases such as AS, rheumatoid arthritis, Crohn's disease, and psoriatic arthritis. TNF-alpha blockers have been effectively used in the treatment of the above-mentioned conditions for several years, but DIL may develop as an important side-effect during treatment (3). Etanercept, infliximab, and adalimumab appear to be the most probable agents that cause this syndrome [also named as TNF-alpha antagonist-induced lupus (TAILS)] (1). TAILS is most frequently observed in female patients with rheumatoid arthritis and Crohn's disease who were treated with infliximab and etanercept therapies and develops after an average of 41 weeks of therapy. Cutaneous features are mostly observed in etanercept-induced lupus, whereas serositis is more frequent in patients undergoing infliximab therapy (8).

It is well known that anti-TNF agents lead to autoantibody positivity (3), with an ANA positivity ranging between 32% and 100% in TAILS (9). The laboratory findings of TAILS are more similar to idiopathic SLE than classical DIL. Anti-dsDNA positivity may be observed in up to 90% in TAILS, which differs from that observed in classic DIL (<1%) (9). Although classical DIL has more (95%) anti-histone antibody positivity, anti-TNF-induced lupus has less anti-histone antibody positivity (17%–57%) (7). Extractable nuclear antigen (ENA) positivity is less than 5% in classical DIL, but it is approximately 10% in TAILS. Hypocomple-

mentemia (positive in 59% of the cases) and cytopenia (61%) may also be present (7).

Our patient had three positive ANA levels, but the levels of anti-ds DNA, anti-histone, or ENA positivity were not determined. ANA became negative after 3 months of discontinuation of the drug. Deterioration of general health and pain and swelling in the wrist and ankle joints were the primary findings in our patient who underwent infliximab therapy for approximately 1 year. ANA was found three positive, although priorly negative. Serositis (pleurisy and pericarditis at the same time) was also present. This complication may be either because of AS itself or because of TAILS. However, the improvement of symptoms after the cessation of infliximab therapy supports the diagnosis of TAILS.

Although there are no evidence-based recommendations for the prevention of the development of TAILS, it is controversial to use additional immunosuppressive agents with anti-TNF drugs (1). In a previous study, it has been claimed that autoantibody positivity may be a precursor for DIL, and that the simultaneous use of methotrexate may avoid the development of autoantibodies (9). The most effective treatment strategy is the immediate withdrawal of drug administration. Patient's symptoms may resolve between 3 weeks and 6 months, but most patients may need immunosuppressive therapy such as steroids, methotrexate, or cyclophosphamide (1,8). We treated our patient with 60 mg/day of methylprednisolone. The patient recovered completely with respect to both the clinical and laboratory findings within 1 month of the above mentioned treatment. In this case, the methylprednisolone administration may be beneficial to treat serositis because of both AS and TAILS.

Renal and neurologic involvements are observed more frequently in TAILS than in classical DIL (7). Although rarely observed in TAILS, visceral involvement (neurologic and renal) was reported in a study from Spain (10); however, the same finding was not found in another study (1). Although our patient had proteinuria, her renal function tests were normal. The proteinuria resolved after the withdrawal of the drug. Because we initiated high doses of steroid treatment, her joint findings also disappeared and her ESR and CRP levels decreased.

Conclusion

During anti-TNF therapy, DIL may develop with life-threatening consequences such as cardiac tamponade. Therefore, the prior emergence of ANA, anti-histone, and anti-dsDNA positivity in a patient with negative autoantibodies alerts us to the development of DIL.

Informed Consent: Written informed consent was obtained patient who participated in this case.

Peer-review: Externally peer-reviewed.

Author Contributions: Concept - I.C.; Design - M.K.; Supervision - A.P.Y.; Resources - I.C.; Materials - I.C.; Data Collection and/or Processing - I.C., M.K.; Analysis and/or Interpretation - A.P.Y.; Literature Search - I.C.; Writing Manuscript - I.C.; Critical Review - A.P.Y.

Conflict of Interest: No conflict of interest was declared by the authors.

Financial Disclosure: The authors declared that this study has received no financial support.

References

1. Williams VL, Cohen PR. TNF alpha antagonist-induced lupus-like syndrome: report and review of the literature with implications for treatment with alternative TNF alpha antagonists. *Int J Dermatol* 2011;50:619-25. [\[CrossRef\]](#)
2. Vasoo S. Drug-induced lupus: an update. *Lupus* 2006;15:757-61. [\[CrossRef\]](#)
3. Desai SB, Furst DE. Problems encountered during anti-tumour necrosis factor therapy. *Best Pract Res Clin Rheumatol* 2006;20:757-90. [\[CrossRef\]](#)
4. De Bandt M, Sibilia J, Le Loët X, Prouzeau S, Fautrel B, Marcelli C, et al. Systemic lupus erythematosus induced by anti-tumour necrosis factor alpha therapy: a French national survey. *Arthritis Res Ther* 2005;7:R545-51. [\[CrossRef\]](#)
5. Griesmann H, Ripka S, Pralle M, Ellenrieder V, Baumgart S, Buchholz M, et al. WNT5A-NFAT signaling mediates resistance to apoptosis in pancreatic cancer. *Neoplasia* 2013;15:11-22. [\[CrossRef\]](#)
6. Marzano AV, Vezzoli P, Crosti C. Drug-induced lupus: an update on its dermatologic aspects. *Lupus* 2009;18:935-40. [\[CrossRef\]](#)
7. Vedove CD, Del Giglio M, Schena D, Girolomoni G. Drug-induced lupus erythematosus. *Arch Dermatol Res* 2009;301:99-105. [\[CrossRef\]](#)
8. Ramos-Casals M, Brito-Zerón P, Muñoz S, Soria N, Galiana D, Bertolaccini L, et al. Autoimmune diseases induced by TNF-targeted therapies: analysis of 233 cases. *Medicine* 2007;86:242-51. [\[CrossRef\]](#)
9. Williams EL, Gadola S, Edwards CJ. Anti-TNF-induced lupus. *Rheumatology (Oxford)* 2009;48:716-20. [\[CrossRef\]](#)
10. Perez-Alvarez R, Perez-de-Lis M, Ramos-Casals M; BIOGEAS study group. Biologics-induced autoimmune diseases. *Curr Opin Rheumatol* 2013;25:56-64. [\[CrossRef\]](#)