



# **Spontaneous Osteonecrosis of the Medial Tibial Plateau: A Rare Differential Diagnosis of Knee Pain**

## **Spontan Medial Tibial Plato Osteonekrozu: Diz Ağrısının Ayrıcı Tanısında Nadir Bir Neden**

Sami KÜÇÜKŞEN, Ali Yavuz KARAHAN, Havva KALKAN\*

Selçuk University Meram Medical School, Department of Physical Medicine and Rehabilitation, Konya, Turkey

Selçuk University Meram Medical School, Department of Radiology, Konya, Turkey

Dear editor,

Acute nontraumatic knee pain can be seen in many conditions, such as transient bone marrow edema syndrome, transient regional osteoporosis of the knee, spontaneous osteonecrosis and insufficiency fractures. Differentiation of these conditions can be troubling to both the radiologists and the clinicians due to overlapping imaging findings and similar clinical presentations.

Clinically, spontaneous osteonecrosis of the medial tibial plateau (SOMTP) is frequently confused with medial meniscus tear and pes anserine bursitis. In the affected region, joint cartilage destruction and osteoarthritis may occur as a result of damage in the supportive trabecular layer of subchondral bone (1,2). If diagnosed early, many patients may have a chance for nonoperative treatment with satisfactory results. However, in patients with advanced-stage disease, surgical procedures such as arthroscopic drilling, high tibial osteotomy and even total knee replacement may be necessary. Therefore, early diagnosis and treatment are very important. To raise awareness of SOMTP among physicians, we report a 49-year-old woman who was diagnosed with SOMTP at an early stage and successfully treated conservatively.

A 49-year-old female patient presented with severe left knee pain of two weeks duration. There was no chronic illness or trauma in her medical history. The pain increased with walking or ascending/descending stairs. She also had nocturnal and

resting pain. Smoking, alcohol consumption or any drug abuse were absent. Her body mass index was 30.7 kg/m<sup>2</sup>. In physical examination, there was no deformity, redness, swelling or warmth in the knee. Tenderness to palpation was found over the medial part of the knee. Range of motion was normal. McMurray's and Apley's tests were painful on the medial side, tests for instability were negative. Laboratory tests including complete blood count, erythrocyte sedimentation rate (ESR), C-reactive protein (CRP), rheumatoid factor, uric acid and lipid profile were normal. Plain radiograph was unremarkable except for minimal degenerative changes. Magnetic resonance imaging (MRI) revealed T2-signal intensity in the medial tibial plateau along with a linear low-intensity subchondral line representing an insufficiency fracture. Coronal T2-weighted MRI showed an area of low signal intensity surrounded by a high-intensity signal caused by edema, compatible with osteonecrosis (Figure 1).

According to the clinical and MRI findings, the patient was diagnosed as having SOMTP. Conservative treatment and follow-up was planned, because lesion was small and diagnosed at an early stage. Considering the increasing prevalence of osteoporosis in osteonecrosis cases, bone mineral density (BMD) was measured by dual-X-ray-absorptiometry and low spinal BMD was observed (total L1-L4 T-score: -3.2). Load on the left knee was reduced by minimizing patient's activities and partial weight-bearing with a walking stick. Local ibuprofen and oral meloxicam 15 mg/day and local cold

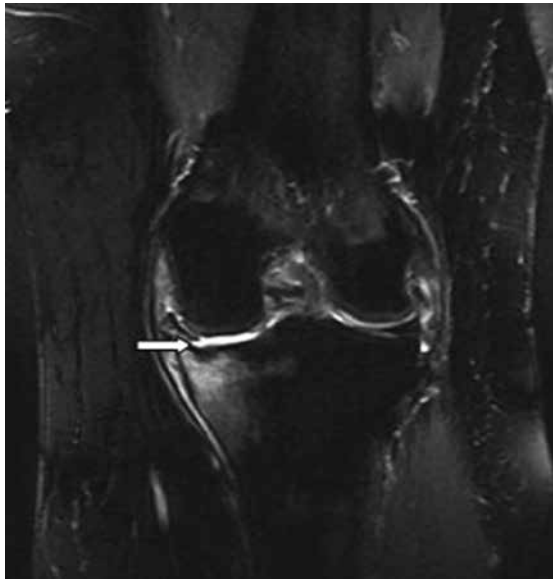


Figure 1: A coronal T2-weighted image with fat saturation showing an osteonecrotic area of low signal intensity (arrow) surrounded by a high-intensity signal caused by edema, compatible with osteonecrosis.

application for 20 minutes three times daily were initiated in order to suppress regional inflammatory process. Conventional transcutaneous electrical nerve stimulation (TENS) was used for 20 minutes twice daily for 15 days to obtain pain relief. Isometric and isotonic strengthening exercises were applied to the quadriceps and hamstring muscles. A lateral wedged insole was prescribed in order to prevent possible genu varum. Once-weekly alendronate 70 mg and daily calcium carbonate 1,000 mg and cholecalciferol 880 IU were initiated for osteoporosis treatment. 3 months later, the pain was diminished significantly and the patient had no limitation in walking and daily activities.

Osteonecrosis is described as cellular death and loss of osseous elements in bone tissue due to insufficient regional blood flow. Osteonecrosis of the knee joint most often affects the medial femoral condyle. Only 2% of all necroses in the knee have been reported to affect the tibial plateau. The precise etiology and pathophysiology of this condition remain unclear. In current trials, the pathogenesis is based on osseous ischemia following vascular insufficiency of the subchondral bone or subchondral stress fracture caused by microtrauma in osteoporotic patients (3). Yamamoto et al. (4) reported that lesions diagnosed as spontaneous osteonecrosis were subchondral insufficiency fractures secondary to osteoporosis and that the osteonecrosis was considered to be the result of a fracture.

Osteonecrosis frequently leads to secondary osteoarthritis developing and rapidly progressing within 8 to 10 weeks of the onset of symptoms (5). Patients diagnosed at earlier stages may benefit from conservative treatment. In these patients, the joint is reposed by completely or partially reducing the load on the joint. Local cold application and nonsteroidal anti-inflammatory drugs (NSAIDs) aim to reduce local inflammation. During this period, isometric quadriceps and hamstring exercises prevent local atrophy. Patients with osteonecrosis should be evaluated for osteoporosis and if necessary, appropriate osteoporosis treatment should be administered.

Due to pain location, SOMTP may be confused with osteochondritis dissecans, medial meniscus pathologies and pes anserine bursitis. Among the differential diagnosis of osteonecrosis, transient bone marrow edema syndrome (TBMO) and transient osteoporosis are of particular interest. TBMO usually affects middle-aged men and, less frequently, women. Within the knee joint, the most common site is on the femoral condyles but TBMO may occur anywhere in the knee. Occasionally, the tibia and patella are affected. Patients present with self-limiting acute knee pain of acute or subacute onset that can mimic meniscal tears. The pain usually resolves within 1 year in parallel with the resolution of the imaging findings. Laboratory tests are usually unhelpful, and histological examination is unnecessary. Transient osteoporosis of the knee is a distinct clinical entity. Extension of bone marrow edema to a non-weight-bearing surface, presence of subchondral sparing, short duration of symptoms before MRI imaging and middle age at presentation are mostly associated with the transient pattern of this disorder.

Consequently, SOMTP should be considered in the differential diagnosis in patients with acute spontaneous knee pain, especially pain at resting and nighttime. Conservative follow-up may be considered in patients with SOMTP diagnosed at an early stage.

## References

1. Zywił MG, McGrath MS, Seyler TM, Marker DR, Bonutti PM, Mont MA. Osteonecrosis of the knee: a review of three disorders. *Orthop Clin North Am* 2009;40:193-211.
2. Patel DV, Breazeale NM, Behr CT, Warren RF, Wickiewicz TL, O'Brien SJ. Osteonecrosis of the knee: current clinical concepts. *Knee Surg Sports Traumatol Arthrosc* 1998;6:2-11.
3. Arnoldi CC, Lemperg K, Linderholm H. Intraosseous hypertension and pain in the knee. *J Bone Joint Surg Br* 1975;57:360-3.
4. Yamamoto T, Bullough PG. Spontaneous osteonecrosis of the knee: the result of subchondral insufficiency fracture. *J Bone Joint Surg Am* 2000;82:858-66.
5. Satku K, Kumar VP, Chong SM, Thambyah A. The natural history of spontaneous osteonecrosis of the medial tibial plateau. *J Bone Joint Surg Br* 2003;85:983-8.