



# ***A case of Polyarteritis Nodosa Mimicking Pyelonephritis and was Misdiagnosed as Inflammatory Bowel Disease***

## ***Piyelonefriti Taklit Eden, Daha Sonra İnflamatuvar Barsak Hastalığı Tanısı Alan Bir Poliarteritis Nodosa Vakası***

Ebubekir ŞENATEŞ, Hatice Seval MASATLIOĞLU, Mehmet Fatih AKDOĞAN\*, Duygu KURTULUŞ\*\*, Mehmet Mahir ATASOY\*\*\*, Ayşe Oya KURDAŞ ÖVÜNÇ

*Haydarpaşa Numune Training and Research Hospital, Department of Gastroenterology, Istanbul, Turkey*

*\*Haydarpaşa Numune Training and Research Hospital, Department of Internal Medicine Clinic, Istanbul, Turkey*

*\*\*Haydarpaşa Numune Training and Research Hospital, Department of Physical Medicine and Rehabilitation, Istanbul, Turkey*

*\*\*\*Dr. Siyami Ersek Thoracic, Cardiac and Vascular Surgery Training and Research Hospital, Department of Radiology, Istanbul, Turkey*

### **Summary**

Polyarteritis nodosa (PAN) is characterized by necrotizing inflammation of small- or medium-sized muscular arteries. Atypical clinical presentation leads to delay in diagnosis. For this reason, it can cause severe morbidity and mortality. Here, we described a case which presented first with fever and left costovertebral angle tenderness, and was misdiagnosed as pyelonephritis. The patient did not benefit from intravenous antibiotherapy that was prescribed in the outpatient clinic and then hospitalized for left lower abdominal pain. No source of fever was found despite detailed physical examination and laboratory investigation. An abdominal ultrasonography showed hyperechogenicity of the left kidney. An abdominal computed tomography was performed for left lower abdominal pain suggesting inflammatory bowel disease findings. Colonoscopy showed an ulcerovegetating and nodular mass surrounding the whole sigmoid colon mucosa and suggesting a malignant tumour. A conventional angiography of the mesenteric artery showed total occlusion of the inferior mesenteric artery. He developed acute abdominal pain and, left hemicolectomy was performed for colonic perforation. Histopathological findings consistent with PAN were detected in the pathological examination of the resected bowel, and the patient was diagnosed with PAN. After initiation of corticosteroid and cyclophosphamide therapy, the clinical status of the patient was improved dramatically with disappearance of fever and relief of abdominal pain. *Turk J Phys Med Rehab 2013;59:79-82.*

**Key Words:** Bowel perforation, inflammatory bowel disease, polyarteritis nodosa

### **Özet**

Poliarteritis nodoza (PAN), küçük veya orta çaplı müküler arterlerin nekrotizan inflamasyonu ile karakterlidir. Klinik prezentasyon, özellikle tanının gecikmesine yol açacak şekilde tipik olmadığında ciddi morbidite ve mortaliteye yol açabilir. Burada ilk olarak ateş, sol yan ağrısı ile başvuran ve yanlışlıkla piyelonefrit tanısı alan bir hasta sunulmaktadır. Ayaktan reçete edilen intravenöz antibiyotik tedavisinden yarar görmeyen hastanın takibinde sol alt kadranda ağrısı gelişti ve hastaneye yatırıldı. Ayrıntılı fizik muayene ve laboratuvar incelemelerine rağmen ateşin kaynağı bulunamadı. Batın ultrasonunda sol böbrekte hiperekojenite saptandı. Sol alt kadranda ağrısı nedeniyle yapılan batın bilgisayarlı tomografisinde inflamatuvar bağırsak hastalığını düşündüren bulgular saptandı. Kolonoskopide sigmoid kolonda lümeni çepçevre saran ve malign tümörü andıran ülserovejetan ve nodüler kitle saptandı. Konvansiyonel mezenter arter anjiyografisinde inferior mezenter arterde total oklüzyon saptandı. Takipte kısa süre sonra akut batın gelişen hasta cerrahiye nakledildi ve barsak perforasyonu tanısıyla opere edildi ve sol hemikolektomi uygulandı. Rezekte bağırsak segmentlerinde PAN ile uyumlu histopatolojik bulgular saptandı ve hastaya PAN tanısı konuldu. Kortikosteroid ve siklofosfamid tedavisi başladıktan sonra hastanın ateşi geriledi ve karın ağrısı geçti. *Türk Fiz Tıp Rehab Derg 2013;59:79-82.*

**Anahtar Kelimeler:** Poliarteritis nodoza, inflamatuvar bağırsak hastalığı, bağırsak perforasyonu

## Introduction

Polyarteritis nodosa (PAN) is a disorder characterized by necrotizing inflammation of the small- or medium-sized muscular arteries, commonly within the kidneys, gastrointestinal (GI) tract, skin, nerves, joints, and the muscles (1). PAN can affect virtually any organ, but has a striking tendency to spare the lungs. Most cases of PAN are idiopathic, although hepatitis B virus (HBV) infection (particularly in patients with a history of intravenous drug abuse), hepatitis C virus infection, and hairy cell leukemia are important in the pathogenesis of some cases (2). Patients with PAN typically present with systemic symptoms (fatigue, weakness, fever and arthralgias) and signs (hypertension, renal insufficiency, neurologic dysfunction, and abdominal pain) of multisystem involvement. Abdominal pain is an early symptom in patients with mesenteric arteritis (3). Progressive disease can result in bowel infarction with perforation (4). When the clinical presentation is not typical, thus lead to delay in diagnosis, it can cause severe morbidity and mortality. Here, we present a case of PAN mimicking initially pyelonephritis and then misdiagnosed as inflammatory bowel disease (IBD).

## Case Report

A 39-year-old man presented to the emergency department of our hospital with fever and left lower abdominal pain for the last 24 hours. In his medical history, he had hypertension for one year and was treated with lisinopril and hydrochlorothiazide.

On admission, he had fever (39°C); physical examination was normal except for left costovertebral angle tenderness. The laboratory findings were as follows: hemoglobin (Hgb) 14.4 g/dL, white blood cells (WBC) 28,000/mL (84% polymorphonuclear leukocytes), creatinine (Cr) 2.3 gr/dL (<1.3), total protein 6.3 g/dl (6.6-8.7), albumin 2.8g/dl (3.4-4.8), erythrocyte sedimentation rate (ESR) 76 mm/h (0-20), C-reactive protein (CRP) 20.4 g/dL (0-0.8). An abdominal ultrasonography (USG) revealed parenchymal hyperechogenicity and decreased dimensions in the left kidney. The patient was diagnosed with pyelonephritis and recommended intravenous ceftriaxone 2 gr/day for a week and sent home. After 1 week without any benefit from this treatment, he admitted to the emergency room again when he had severe left lower abdominal pain. On the second admission, the results of laboratory studies revealed; Hgb 14 g/dL, WBC 23,690/mL (80% polymorphonuclear leukocyte), Cr 1.2 gr/dL (<1.3), ESR 96 mm/h (0-20 mm/h), CRP 35 gr/dL (0-0.8), alanine aminotransferase (ALT) 46 IU/L (<41), serum iron 24 IU/L (59-158), serum total iron binding capacity 149 (291-430), while all the other parameters were within normal limits. Repeated abdominal USG revealed decreased dimensions of the left kidney and bilateral parenchymal hyperechogenicity, which was more prominent in the left kidney. He was hospitalized with presumed diagnosis of pyelonephritis and his antibiotherapy was changed to ertapenem 1 gr IV qid. In the first day of hospitalization, he was found to have arterial hypertension of 190/100 mmHg and consulted with an internist. The internist suspected for secondary hypertension and recommended to perform renal color Doppler USG, 24-h urinalysis for proteinuria, creatinine clearance, and eye examination. Brucella

agglutination test, VDRL-RPR, acid-resistant bacilli in urine, blood culture, PPD test and Löwenstein-Jensen incubation culture were also performed. There was decreased dimensions and hyperechogenicity of the left kidney on renal Doppler USG. He was found to have grade III hypertensive retinopathy (HTRP) on eye examination. Creatinine clearance was 96 ml/min/d and 80 mg/day microalbuminuria was found on 24-h urinalysis. PPD test was anergic. Brucella agglutination test, cultures of urine and blood, VDRL, ARB in urine tests were negative. The viral hepatitis markers were as follows: HBsAg (-), Anti-HBs (-), anti-HBc total (+) Anti-HCV (-), Toxoplazma IgG (+), IgM (-), CMV IgG (+), IgM (-), Rubella IgG (+), IgM (-). Since no significant response was observed after the treatment with ertapenem, his antibiotherapy was switched to imipenem+cilastatin 500 mg IV qid. For secondary hypertension, an MRI-angiography was performed and hypoplasia in the left renal artery, little irregularity in distal abdominal aorta and bilateral iliac arteries were found. Abdominal USG, which was performed for acute abdominal pain, showed ileus findings with bowel dilatation, gas distension, decreased bowel movements and minimal fluid collection. Following these USG findings, an abdominal computed tomography (CT) was performed and thickening of the wall of the distal part of the small intestine and the transverse colon, splenic flexura and descendent colon were observed. He was consulted with gastroenterology and then transferred to the gastroenterology clinic with presumed diagnosis of IBD, after 15 days of hospitalization.

After his transfer, performed colonoscopy demonstrated ulcers as large as 0.5 to 2 cm in diameter in the proximal sigmoid colon extending to the distal sigmoid colon. The rectum was normal. Tissue samples were taken around and from the ulcers for pathology, M. tuberculosis PCR and M. tuberculosis culture. The previous aerobic, anaerobic and M. tuberculosis cultures remained negative. Thoracic and lumbar spine CT, total body bone scintigraphy, transthoracic and transesophageal echocardiography tests were normal. In the follow-up period, bilateral inguinal enlarged lymph nodes were detected on physical examination. An excisional biopsy of the inguinal lymph node from the left inguinal area showed only reactive hyperplastic changes.

One month later, control colonoscopy revealed an ulcerovegetating and nodular mass surrounding the whole sigmoid colon mucosa and suggesting malign tumor and not allowing the colonoscope to pass through (Figure 1). Multiple big biopsies were taken from the mass using snare and jumbo forceps. Pathologic examination of the mass showed only exudate and granulation of the tissues, but not malignity.

The serum autoantibodies such as ANA, Anti-ds-DNA, ANCA (anti-MPO and anti-PR3), anti-CCP, AMA, LKM-1, ASMA, and tumor markers of  $\alpha$ -fetoprotein, CEA, CA 19.9 were negative and serum protein electrophoresis was normal. Bone marrow aspiration and biopsy were unremarkable except for little increase in plasma cells and lambda light chain, but were not diagnostic. A little increase was also found in kappa light chain in urine immunoelectrophoresis. Physical examination of the ear-nose-throat was normal and paranasal sinus CT was normal except for deviation of the septum nasi.

Because the Quantiferon-GOLD test was found to be positive, antituberculosis treatment was started with 4 drugs (isoniazid, rifampin, pyrazinamide and ethambutol), although his past and family history was unremarkable for tuberculosis. The patient did not benefit from one month period of antituberculosis treatment regarding fever and abdominal pain and, the antituberculosis treatment was stopped.

After discontinuation of the antituberculosis treatment, the abdominal pain and fever persisted. Since he had ongoing constitutional symptoms with negative serology and cultures, a conventional mesenteric artery angiography was performed to rule out polyarteritis nodosa. It showed an occlusion in the inferior mesenteric artery (Figure 2).

A vasculitic process was suggested while he complained of severe abdominal pain and free air was seen on the standing abdominal x-ray. Then, he was transferred to the

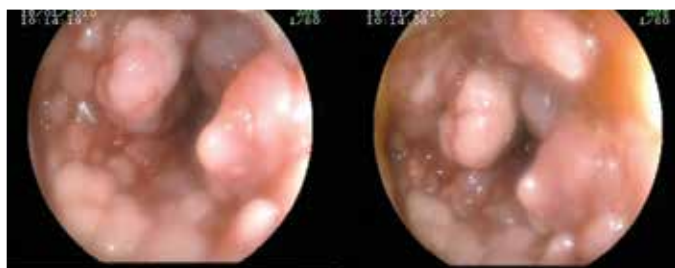


Figure 1. Colonoscopy revealed ulcerovegetating and nodular mass surrounding the whole sigmoid colon mucosa and suggesting malign tumour and did not allow the colonoscope to pass through.

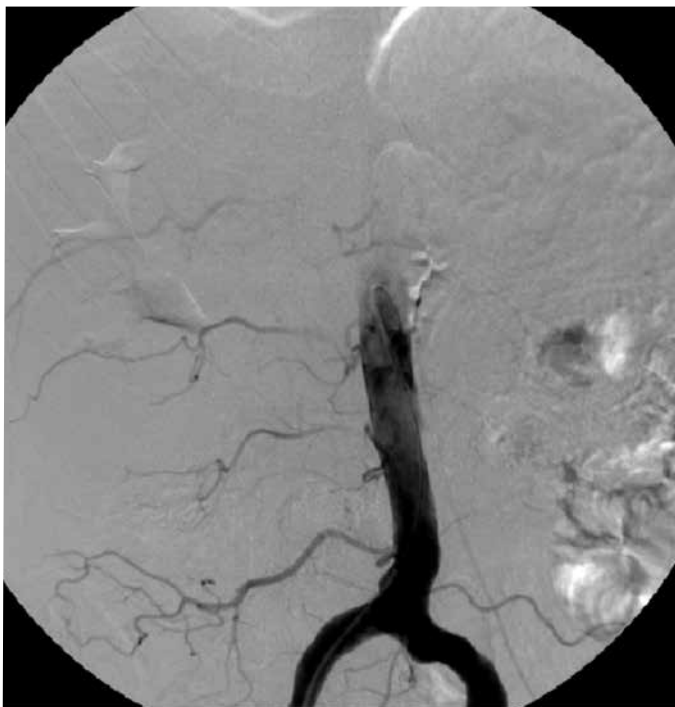

Figure 2. A conventional mesentery artery angiography showed an occlusion in the inferior mesentery artery.

surgery and was operated. The surgeon confirmed the large bowel perforation and performed left hemicolectomy with colostomia. Pathological examination of the resected bowel segment was as follows: diffuse mucosal hemorrhagic infarct, presence of multifocal ulceration, transmural hyperemia and edema, fibrinoid necrosis in the vessel walls, and perforation of the colon wall. After all these findings, the patient was diagnosed as having PAN, and corticosteroid (1 mg/kg/day) and cyclophosphamide 1 g/month was introduced immediately.

After initiation of corticosteroid and cyclophosphamide therapy, the clinical status of the patient dramatically improved with disappearance of fever and relief of abdominal pain. The enlarged lymph nodes regressed after one month of therapy. During follow-up of 6 months, he has been doing well. In the follow-up period, the corticosteroid treatment was tapered and cyclophosphamide was planned for 12 months.

## Discussion

PAN is a necrotizing, focal segmental vasculitis that affects the small- or medium-sized muscular arteries in many different organ systems. The variable clinical presentation and the rarity of the disease often results in a delayed diagnosis (5). Patients with PAN typically present with systemic symptoms and signs of multisystem involvement (6).

The presence of PAN may be suspected from the clinical and radiologic findings, but the diagnosis should be confirmed by biopsy of the clinically affected organ (6). The diagnostic tool alternative to biopsy is conventional mesenteric or renal arteriography (7,8). Less invasive angiography techniques (e.g. CT and MRI), can also be used (9,10), however, they are not useful to detect very little aneurysms or occluded small vessels.

Renal involvement occurs in 6% to 66% of patients as a result of ischemia from stenosis of renal arteries, sparing the glomeruli (11-13). Peripheral neuropathy is a manifestation in 38% to 72% of patients, with mononeuritis multiplex involving the longest nerves first (5). Skin lesions, in 11% to 58% of patients, include livido reticularis, splinter hemorrhages, and palpable purpura (13,14).

GI involvement occurs in 14% to 65% of patients with PAN and is a major cause of morbidity and mortality (15-17). Abdominal complaints develop over weeks or months, with pain being the most common symptom (16). Postprandial abdominal pain from ischemia is the most common symptom (5). Ischemia due to vasculitis affects the small intestine more commonly than other areas of the GI tract (3). The transverse colon is rarely involved (18). Ischemic colitis presents with abdominal pain and diarrhea, sometimes bloody, often requiring surgery (19). If ischemia is limited to the mucosa or submucosa, ulceration and bleeding may occur. When transmural ischemia develops, there is necrosis of the bowel wall, (20) perforation, (21) and infarction, associated with a poor prognosis (4).

The most common causes of an acute abdomen in PAN are bowel infarction, perforation, cholecystitis, and gallbladder infarctions (16,22). Patients should be referred to a surgeon for persistent tenderness, especially with rebound or guarding, and/or with a high lactate level. Early treatment of perforations is essential to reduce the significant mortality that is associated with an acute abdomen in this disease.

Arteriography is a primary modality used to diagnose PAN, being positive in more than 60% of patients (16). Vascular lesions tend to occur at branching points; they are focal and segmental in different stages of development (23). In the chronic stage, fibroblast proliferation results in wall thickening, producing stenosis or occlusion (24). CT scan shows bowel wall thickening with the target sign. The small intestine is the most commonly affected part of the GI tract, followed by the mesentery and colon (25).

Corticosteroids along with a potent immunosuppressive agent, particularly cyclophosphamide, are the mainstay of treatment for hepatitis B- and C-negative PAN. Cyclophosphamide, added particularly in the presence of severe GI involvement, reduces the incidence of relapse but does not change the 10-year survival rate (26,27).

Our patient firstly presented with abdominal pain and tenderness of left costovertebral angle that mimicking pyelonephritis. After one month of treatment with antibiotics and antituberculosis drugs, the abdominal pain remained as the major symptom and it mimicked IBD on the imaging studies. Intravenous pyelography demonstrated atrophy in the left kidney, probably due to the stenosis of the left renal artery. Our patient was infected with HBV that he was cleared but did not develop immunity against it, reflected as HBsAg (-), anti-HBs (-), and antiHbc total (+). After imaging studies and colonoscopy, the findings suggested IBD (Crohn's disease), but we could not reach to the whole parts of the colon and terminal ileum because of subtotal obstruction of the distal sigmoid colon. Pathologic examination of the biopsies taken from this area revealed nonspecific findings for IBD and there were some clues for ischemic colitis. The conventional mesenteric angiography confirming total occlusion of the inferior mesenteric artery and necrotizing inflammation of the muscular arteries of the colonic wall on the pathological examination clarified the diagnosis of PAN.

In conclusion, PAN is a systemic necrotizing vasculitis with pendulum manifestations in the GI tract. Although rare, it is important to diagnose because the prognosis is poor without proper treatment.

#### Conflict of Interest

Authors reported no conflicts of interest.

#### References

1. John H. Stone. Polyarteritis nodosa. In: Imboden JB, Hellmann DB, Stone JH, editors. *Current Rheumatology Diagnosis and Treatment*. 1st ed. USA: Lange Medical Books/McGraw-Hill; 2004. p. 267-72.
2. Guillevin L, Mahr A, Callard P, Godmer P, Pagnoux C, Leray E, et al. Hepatitis B virus-associated polyarteritis nodosa: Clinical characteristics, outcome, and impact of treatment in 115 patients. *Medicine (Baltimore)*. 2005;84:313-22.
3. Pagnoux C, Mahr A, Cohen P, Guillevin L. Presentation and outcome of gastrointestinal involvement in systemic necrotizing vasculitides: analysis of 62 patients with polyarteritis nodosa, microscopic polyangiitis, Wegener granulomatosis, Churg-Strauss syndrome, or rheumatoid arthritis-associated vasculitis. *Medicine (Baltimore)*. 2005;84:115-28.
4. Zizic TM, Classen JN, Stevens MB. Acute abdominal complications of systemic lupus erythematosus and polyarteritis nodosa. *Am J Med* 1982;73:525-31.
5. Ebert EC, Hagspiel KD, Nagar M, Schlesinger N. Gastrointestinal involvement in polyarteritis nodosa. *Clin Gastroenterol Hepatol* 2008;6:960-6.
6. Hunder GG, John H Stone JH. Clinical manifestations and diagnosis of polyarteritis nodosa. From [www.Uptodate.com](http://www.Uptodate.com)
7. Balow JE. Renal vasculitis. *Kidney Int* 1985;27:954-64.
8. Sato O, Conn DL. Polyarteritis and microscopic polyangiitis. In: Klippel JH, Dieppe PA, editors. *Rheumatology*. St Louis: Mosby; 2003.
9. Kato T, Fujii K, Ishii E, Wada R, Hidaka Y. A case of polyarteritis nodosa with lesions of the superior mesenteric artery illustrating the diagnostic usefulness of three-dimensional computed tomographic angiography. *Clin Rheumatol* 2005;24:628-31.
10. Schmidt WA. Use of imaging studies in the diagnosis of vasculitis. *Curr Rheumatol Rep* 2004;6:203-11.
11. Cohen RD, Conn DL, Ilstrup DM. Clinical features, prognosis, and response to treatment in polyarteritis. *Mayo Clinic Proc* 1980;55:146-55.
12. Abu-Shakra M, Smythe H, Lewtas J, Badley E, Weber D, Keystone E. Outcome of polyarteritis nodosa and Churg-Strauss syndrome. An analysis of twenty-five patients. *Arthritis Rheum* 1994;37:1798-803.
13. Agard C, Mouthon L, Mahr A, Guillevin L. Microscopic polyangiitis and polyarteritis nodosa: how and when do they start? *Arthritis Rheum* 2003;49:709-15.
14. Frohnert P, Sheldon GS. Long-term follow-up study of periarteritis nodosa. *Am J Med* 1967;43:8-14.
15. Guillevin L, Le Thi Huong D, Godeau P, Jais P, Wechsler B. Clinical findings and prognosis of polyarteritis nodosa and Churg-Strauss angiitis: a study in 165 patients. *Br J Rheumatol* 1988;27:258-64.
16. Levine SM, Hellmann DB, Stone JH. Gastrointestinal involvement in polyarteritis nodosa (1986-2000): presentation and outcomes in 24 patients. *Am J Med* 2002;112:386-91.
17. Fortin PR, Larson MG, Watters AK, Yeadon CA, Choquette D, Esdaile JM. Prognostic factors in systemic necrotizing vasculitis of the polyarteritis nodosa group--a review of 45 cases. *J Rheumatol* 1995;22:78-84.
18. Maeda K, Hayashi Y, Morita I, Matsuoka O, Nishiyama M, Nishimura H, et al. Recurrent Dieulafoy's ulcers in the stomach and colonic perforation caused by polyarteritis nodosa: report of a case. *Gastrointest Endosc* 2006;63:349-52.
19. Ruiz-Iratorza G, Egurbide MV, Aguirre C. Polyarteritis nodosa presenting as ischaemic colitis. *Br J Rheumatol* 1996;35:1333-4.
20. Becker A, Mader R, Elias M, Lev A, Sayfan J. Duodenal necrosis as the presenting manifestation of polyarteritis nodosa. *Clin Rheumatol* 2002;21:314-6.
21. de Carpi JM, Castejón E, Masiques L, Vilar P, Antón J, Varea V. Gastrointestinal involvement in pediatric polyarteritis nodosa. *J Pediatr Gastroenterol Nutr* 2007;44:274-8.
22. Gündoğdu HZ, Kale G, Tanyel FC, Büyükpamukçu N, Hiçsönmez A. Intestinal perforation as an initial presentation of polyarteritis nodosa in an 8-year-old boy. *J Pediatr Surg* 1993;28:632-4.
23. Miller DL. Angiography in polyarteritis nodosa. *AJR Am J Roentgenol* 2000;175:1747-8.
24. Stanson AW, Friese JL, Johnson CM, McKusick MA, Breen JF, Sabater EA, et al. Polyarteritis nodosa: spectrum of angiographic findings. *Radiographics* 2001;21:151-9.
25. Ha HK, Lee SH, Rha SE, Kim JH, Byun JY, Lim HK, et al. Radiologic features of vasculitis involving the gastrointestinal tract. *Radiographics* 2000;20:779-94.
26. Fauci AS, Katz P, Haynes BF, Wolff SM. Cyclophosphamide therapy of severe systemic necrotizing vasculitis. *N Engl J Med* 1979;301:235-8.
27. Guillevin L, Cohen P, Mahr A, Arène JP, Mouthon L, Puéchal X, et al. Treatment of polyarteritis nodosa and microscopic polyangiitis with poor prognosis factors: a prospective trial comparing glucocorticoids and six or twelve cyclophosphamide pulses in sixty-five patients. *Arthritis Rheum* 2003;49:93-100.