

# Effects of splinting and three injection therapies (corticosteroid, autologous blood and prolotherapy) on pain, grip strength, and functionality in patients with lateral epicondylitis

Samet Sancar Kaya<sup>1</sup>, Gökhan Yardımcı<sup>2</sup>, Hamit Göksu<sup>1</sup>, Hakan Genç<sup>3</sup>

<sup>1</sup>Department of Algology, Ankara City Hospital, Ankara, Türkiye

<sup>2</sup>Department of Physical Medicine and Rehabilitation, Gaziler Physical Therapy and Rehabilitation Training and Research Hospital, Ankara, Türkiye

<sup>3</sup>Department of Physical Medicine and Rehabilitation, Ankara Training and Research Hospital, Ankara, Türkiye

Received: December 20, 2020 Accepted: May 03, 2021 Published online: June 01, 2022

## ABSTRACT

**Objectives:** This study aims to compare the efficacy of the wrist splint and the injection of corticosteroid, autologous blood, and hypertonic dextrose in the treatment of lateral epicondylitis (LE).

**Patients and methods:** A total of 120 patients (43 males, 77 females; mean age: 45.7±7.7 years; range, 18 to 65 years) diagnosed with LE between December 2013 and June 2015 were included in the study and randomized into four groups. The first group was administered 20 mg methylprednisolone acetate + 2 mL 2% prilocaine, the second group 2 mL venous blood + 0.5 mL prilocaine, and the third group 2 mL 30% dextrose + 0.5 mL prilocaine injections. A second injection was administered to the third group one month later. The fourth group was recommended to use only a wrist splint. Pre-treatment and post-treatment evaluations of the patients were carried out at one and six months by the Visual Analog Scale (VAS) in terms of pain, by Patient-Rated Tennis Elbow Evaluation (PRTEE) questionnaire in terms of functional level, and by the Jamar dynamometer in terms of grip strength.

**Results:** In all groups, VAS values at one and six months after treatment were found to be lower in comparison to baseline. Except for the splint group, a significant improvement was observed in all three injection groups in terms of grip strength and PRTEE values at six months compared to the baseline values. In the comparison of the groups, no significant difference was observed in terms of improvement in VAS scores and grip strength. While corticosteroid injection was significantly effective in terms of PRTEE pain, function, and total scores only at one month, the autologous injection was effective in terms of PRTEE function and total scores at only six months after treatment. There were no significant differences for splint and prolotherapy groups in terms of PRTEE scores.

**Conclusion:** Corticosteroid injection, autologous blood injection, and prolotherapy are effective and safe long-term methods in LE treatment.

**Keywords:** Autologous blood injection, corticosteroid injection, lateral epicondylitis, prolotherapy.

Lateral epicondylitis (LE) is the most common cause of elbow pain, is tendinosis at attachment of wrist extensors to the lateral epicondyle. It was first defined in 1873 by Runge.<sup>[1]</sup> The disease is mostly identified at the ages of 45-55, and its prevalence was

reported to be 1.3%.<sup>[2]</sup> It involves the dominant arm more frequently. A degenerative tendinopathy process, characterized with neovascularization and increased fibroblasts in consequence of recurrent microtraumas, is considered in the etiopathogenesis of the disease.<sup>[1]</sup>

**Corresponding author:** Samet Sancar Kaya, MD. Ankara Şehir Hastanesi, Algoloji Kliniği, 06800 Çankaya, Ankara, Türkiye.

e-mail: sametsancarkaya@hotmail.com

*Cite this article as:*

Kaya SS, Yardımcı G, Göksu H, Genç H. Effects of splinting and three injection therapies (corticosteroid, autologous blood and prolotherapy) on pain, grip strength, and functionality in patients with lateral epicondylitis. Turk J Phys Med Rehab 2022;68(2):205-213.

Excessive use of wrist extensor muscles and recurring forearm supination and pronation cause degeneration at the musculotendinous junction of the extensor carpi radialis brevis muscle.

Lateral epicondylitis is diagnosed as lateral elbow pain with active wrist extension, resistive during elbow extension, and forearm supination.<sup>[3]</sup> Generally, there is a reduction in grip strength.

There is no common consensus in LE treatment. Resting, use of orthoses, physical therapy modalities, nonsteroidal anti-inflammatory drugs (NSAIDs), and injections (corticosteroid, autologous blood, platelet-rich plasma, prolotherapy) are commonly used treatments. Surgical treatment can be applied for around 10% of patients whose pain does not respond to these treatment modalities.<sup>[4]</sup>

It was determined that corticosteroid (CS) injections were not effective in the long term, even though they reduced pain in the acute period.<sup>[5]</sup> In another study, it was reported that LE limited itself without any treatment.<sup>[6]</sup> It has been reported that the wait-and-see approach is more effective than CS injections in the long term.<sup>[7]</sup> In recent years, autologous blood (AB) injections and prolotherapy are increasingly more used in LE treatment since they improve tendon regeneration.<sup>[8,9]</sup> Contradictory results have been reported in the majority of studies on LE treatment. The superiority of one treatment over another has not been evidenced clearly.

This study aimed to compare the use of wrist splints, CS injections, AB injections, and prolotherapy in LE treatment and demonstrate whether AB injection and prolotherapy can be alternatives to steroid injection in the long term.

## PATIENTS AND METHODS

A total of 208 patients who presented with elbow pain to Ankara Training and Research Hospital, Department of Physical Medicine and Rehabilitation between December 2013 and June 2015 and were subsequently diagnosed with LE were evaluated in the single-blinded randomized controlled trial. Lateral epicondylitis diagnosis was based on the elbow pain, sensitivity on lateral epicondyle by palpation, and pain in the lateral epicondyle increasing with resistant wrist extension.<sup>[10]</sup> Patients younger than 18 and older than 65 years of age and those with a history of injection treatment for LE, pain for less than one month, a Visual Analog Scale (VAS) score below 40, ipsilateral shoulder or cervical disease, a diagnosis of fibromyalgia, carpal

tunnel syndrome, or inflammatory disease, a history of trauma in the elbow, bilateral elbow pain, a coagulation disorder, and a history of allergic reaction for local anesthetic drugs were excluded from the study,<sup>[11]</sup> and the remaining 120 patients (43 males, 77 females; mean age:  $45.7 \pm 7.7$  years; range, 18 to 65 years) were included in the study.

The sealed numbered envelope method was used for casual randomization by an administrative assistant. The patients were randomized into four groups after physical examination and evaluation by a physiatrist. The first group was administered 20 mg methylprednisolone acetate + 2 mL 2% prilocaine, the second group 2 mL venous blood + 0.5 mL prilocaine, and the third group 2 mL 30% dextrose + 0.5 mL prilocaine. A second injection was administered to patients in the third group one month later. The fourth group was recommended to use only a wrist splint for 6 to 8 h during the daytime. The wrist splint allowed wrist and hand movements, fixed at  $5-10^\circ$  dorsiflexion to improve loading stress on the common extensors of the wrist. The outcomes were assessed by a physician who was completely unaware of the patient groups. All injections were performed using a 22-G 30-mm needle under sterile conditions and by a specialized physiatrist for musculoskeletal injection. Lateral epicondylitis injection was applied in the lateral decubitus position. After the injector was placed at the most tender area, the clockwise peppering technique was used to obtain a wider zone of drug delivery. Ice massage was applied for 5-10 min after the injection. The patients were advised to avoid movements that would force their elbows even if the pain subsided after the injection. They were also recommended to take acetaminophen 500 mg orally during the first 48 h after injections in case of pain. The patients were asked not to use NSAIDs during the follow-up period.

Pre-treatment and post-treatment evaluations of the patients were carried out at the first and sixth months by the VAS in terms of pain, by the Patient-Rated Tennis Elbow Evaluation (PRTEE) questionnaire in terms of functional level, and by Jamar Dynamometer (Sammons Preston, Bolingbrook, IL, USA) in terms of grip strength consecutively. All injections were performed by one researcher and patient evaluations were made by another researcher.

Visual Analog Scale is a visual pain scale. The absence of pain is demonstrated with 0 points, and the most severe state is indicated by 10 points. The patients were asked to demonstrate their pain levels on the scale.<sup>[12]</sup>

Patient-Rated Tennis Elbow Evaluation is a test evaluating pain with five questions and functional level with 10 questions (six questions on specific activities and four questions on daily life activities). The best score is 0, and the worst score is 100.<sup>[13]</sup>

Pain-free grip strength was evaluated by the Jamar dynamometer (Sammons Preston, Bolingbrook, IL, USA). All measurements were made in sitting position, shoulders in 60° flexion and abduction, the elbow in full extension, the forearm in pronation, and the wrist in 20° dorsiflexion. The patients were asked to squeeze the dynamometer up to their pain threshold in this position. The measurements were made three times, and the mean value was calculated.<sup>[12]</sup>

### Statistical analysis

The data were analyzed using the IBM SPSS version 22.0 software (IBM Corp., Armonk, NY, USA). The sample size estimated according to previous similar studies was calculated as 30 patients, considering a power of 80% and a probable drop rate of 10% with a moderate size effect ( $f=0.45$ ).<sup>[14]</sup> Descriptive statistics were presented as mean  $\pm$  standard deviation, median (interquartile range), frequency distribution, and percentage. Pearson's chi-square test was used in

the evaluation of categorical variables. Conformity of variables to normal distribution was reviewed by using visual (histogram and probability graphics) and analytical methods (Shapiro-Wilk test). The Friedman test was used to review if a variation in time-dependent measurements of each group was significant. Where time-dependent variations were significant, Wilcoxon signed-rank test was applied to determine control time causing difference. Split-plot analysis of variance (ANOVA) was used to evaluate variation between the groups. In case of variation between the groups, multiple comparisons were made via the Bonferroni correction. Level of statistical significance was accepted as  $p<0.05$ .

## RESULTS

Among 120 eligible patients included in this trial, 104 completed the study (Figure 1). One patient, who was administered an AB injection, developed hand drop; however, the patient improved in 24 h without any sequelae. Another complication didn't occur in the study.

At baseline, no significant differences were found between the demographic and clinical features of the groups (Table 1).

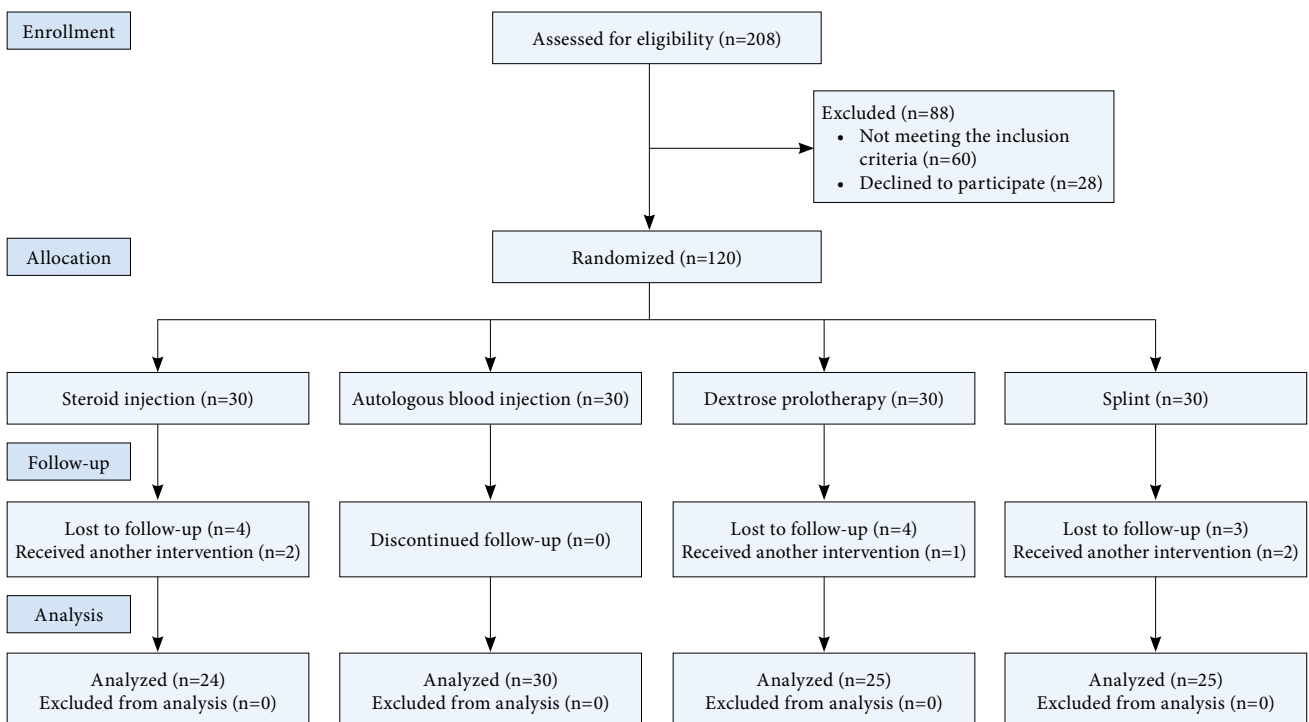


Figure 1. Participant flow through the study.

**TABLE 1**  
Clinical and demographic data of the groups at baseline

	Steroid group (n=24)			Autologous blood group (n=30)			Prolotherapy group (n=25)			Splint group (n=25)			p
	n	%	Mean±SD	n	%	Mean±SD	n	%	Mean±SD	n	%	Mean±SD	
Age (year)			47.8±7.1			46.7±8.7			45.4±7.9			43.0±7.1	0.375*
Sex													
Female	18	75		18	60		15	60		18	60		0.541†
Extremity held													0.065†
Dominant	10	41.7		22	73.3		18	72		17	68		
Non-dominant	14	58.3		8	26.7		7	28		8	32		
Pain duration (month)			5.0±6.3			5.6±7.7			3.2±2.6			3.0±1.8	0.408*
VAS (0-100)			70.0±15.6			76.3±16.1			73.9±15.9			66.3±19.1	0.278*
Grip strength (kg)			21.9±10.8			22.98±7.98			22.3±9.3			28.3±13.0	0.313*
PRTEE													
Pain			29.7±9.4			34.4±16.1			32.7±8.4			28.7±8.1	0.158*
Function			29.4±11.6			32.9±9.5			31.0±10.1			24.7±10.4	0.160*
Total			59.2±19.6			67.4±16.4			73.9±15.9			53.5±16.2	0.104*

SD: Standard deviation; VAS: Visual analog score; PRTEE: Patient-Rated Tennis Elbow Evaluation; †: Chi-square test; \* ANOVA test.

Significant improvements compared to the baseline were observed in pain levels of all groups in pain evaluations at the first and sixth months (Table 2). While grip strength demonstrated a significant increase from the baseline at first and sixth months after injection in CS injection and AB injection groups, a significant increase was not observed in the splint group. In the prolotherapy group, a significant increase in grip strength was not detected at one month after injection; however, grip strength increased at a statistically significant level compared to baseline at six months (Table 2).

Except for the splint group, a significant improvement was noted in the PRTEE pain, function, and total scores of three injection groups at both one and six months compared to baseline (Table 3).

In the comparison of groups, no significant difference was observed in terms of improvement in VAS scores and grip strength (Table 4). While CS injection was significantly effective for PRTEE pain, function, and total scores only at one month, AB injection was effective for PRTEE function and total scores only at six months. No significant differences

**TABLE 2**  
The comparison of groups regarding median values of VAS and grip strength at baseline, one month, and six months

	Baseline		Month 1		Month 6		p†
	Median	IQR	Median	IQR	Median	IQR	
VAS							
Steroid group	70	20	20*	34*	20*	60*	<0.001
Autologous blood group	80	30	50*	30*	10*	33*	<0.001
Prolotherapy group	70	20	50*	20*	20*	50*	<0.001
Splint group	60	40	40*	20*	30*	80*	0.025
Grip strength							
Steroid group	21.5	15	22*	12*	25*	9*	0.002
Autologous blood group	24	8	25*	11*	29.5*	13*	<0.001
Prolotherapy group	22	14	25	15	28*	14*	<0.001
Splint group	24	18	23	19	25	21	0.223

VAS: Visual Analog Score; IQR: Interquartile range; \* Difference is statistically significant compared to baseline (p<0.05); Wilcoxon signed-rank test; † Friedman test.

**TABLE 3**  
Within-group comparisons of median values of PRTEE score at the baseline, month 1 and month 6

	Baseline		Month 1		Month 6		p†
	Median	IQR	Median	IQR	Median	IQR	
<b>PRTEE pain</b>							
Steroid group	29.5	14.8	11*	13.8*	9.5*	23.5*	<0.001
Autologous blood group	35	15.3	24*	22.8*	9.0*	16.3*	<0.001
Prolotherapy group	33	9.0	22*	15*	6.0*	21.0*	<0.001
Splint group	28	11.0	21	10	10.0	36.0	0.292
<b>PRTEE function</b>							
Steroid group	28.75	21.9	7.25*	19.3*	7*	20.9*	<0.001
Autologous blood group	34.25	16.4	17.5*	25.5*	5.0*	14.5*	<0.001
Prolotherapy group	32.0	17.0	23.5*	15.0*	6.0*	15.5*	<0.001
Splint group	25.5	20.0	14.0	20.0	14.0	35.0	0.086
<b>PRTEE total</b>							
Steroid group	60.25	31.8	18.25*	36.8*	16.5*	43.9*	<0.001
Autologous blood group	67.25	26.9	45.25*	43.9*	13.25*	30.5*	<0.001
Prolotherapy group	61.5	20.5	49.5*	25.0*	12*	42.5*	<0.001
Splint group	53.5	30.5	35.0	26.5	27.5	70.0	0.203

PRTEE: Patient-Rated Tennis Elbow Evaluation; IQR: Interquartile range; \* Difference is statistically significant compared to baseline (p<0.05); Wilcoxon signed-rank test; † Friedman test.

**TABLE 4**  
The comparison of groups regarding the mean differences of VAS and grip strength at baseline-one month and baseline-six months

	Baseline-Month 1	Baseline-Month 6
	Mean±SD	Mean±SD
<b>VAS</b>		
Steroid group	41.2±31.7	37.9±39.5
Autologous blood group	30.0±32.3	47.6±32.1
Prolotherapy group	22.4±23.1	56.0±34.6
Splint group	20.0±20.9	28.1±28.6
P value†	0.110	0.093
<b>Grip strength</b>		
Steroid group	-4.17±4.4	-3.96±5.4
Autologous blood group	-3.87±7.6	-7.97±8.0
Prolotherapy group	-2.0±4.9	-5.95±5.5
Splint group	-2.1±1.9	-2.64±2.7
P value†	0.513	0.050

VAS: Visual Analog Score † ANOVA test.

were found between splint and prolotherapy groups in terms of PRTEE scores (Table 5).

## DISCUSSION

We evaluated the effects of splinting and three different injection treatment modalities for the treatment of LE. Also known as tennis elbow, LE is defined as pain related to tendinosis, observed where wrist extensors attach to the lateral epicondyle. It

**TABLE 5**  
The comparison of groups regarding the mean differences of the PRTEE score at baseline-one month and baseline-six months

	Baseline-Month 1	Baseline-Month 6
	Mean±SD	Mean±SD
<b>PRTEE pain</b>		
Steroid group	17.8±10.9*	16.4±18.9
Autologous blood group	13.2±12.2	23.6±13.7
Prolotherapy group	10.0±11.1	20.5±13.2
Splint group	6.2±10.2	10.7±12.8
P value†	0.027	0.081
<b>PRTEE function</b>		
Steroid group	18.3±12.3*	17.7±17.8
Autologous blood group	13.6±13.0	24.5±12.7*
Prolotherapy group	9.1±8.9	21.1±14.1
Splint group	6.2±8.3	9.4±8.7
P value†	0.014	0.026
<b>PRTEE total</b>		
Steroid group	36.2±21.4*	34.1±35.6
Autologous blood group	26.9±22.9	48.1±25.1*
Prolotherapy group	19.1±18.6	41.6±26.1
Splint group	12.4±15.6	20.1±19.7
P value†	0.008	0.036

PRTEE: Patient-Rated Tennis Elbow Evaluation; \* Difference with splint group is statistically significant (p<0.05); † ANOVA test; Bonferroni post-hoc test.

causes labor force at a significant rate due to pain and decreased grip strength in patients. Even though the term epicondylitis refers to an inflammatory event, evidence of active inflammation was not found

in histopathological studies.<sup>[15]</sup> Angiofibroplastic hyperplasia and poor scar tissue occur in response to recurring microtraumas in the tendon, and consequently, complete healing does not take place. Since the etiology and physiopathology of LE are not clear, there is no common consensus on its treatment. The common purpose of the treatment is to reduce pain, increase grip strength, and improve functional state. In our study, we determined that AB injection and prolotherapy, which are regenerative treatment methods with increased popularity in recent years, and CS injection were effective and safe both in the short and long term.

In LE treatment, it is crucial to avoid repeated wrist movements, heavy lifting, and activities that increase the pain.<sup>[16]</sup> Therefore, wrist splints and elbow orthoses are frequently used. Altan and Kanat<sup>[17]</sup> reported that, in LE treatment, both lateral epicondyle straps and wrist splints reduce pain, and there was no difference between the two splints for long-term efficacy. Garg et al.<sup>[18]</sup> demonstrated that wrist extension splint reduced the pain more effectively than forearm bracing in patients with LE. Belhan and Karakurt<sup>[19]</sup> compared lateral epicondyle strap with steroid injection in patients with LE and found the steroid injection to be more effective than the lateral epicondyle strap. Struijs et al.<sup>[20]</sup> did not establish any differences between orthoses, topical NSAIDs, and physical therapy in their systematic analysis and Cochrane compilation, where they investigated their efficacies in LE treatment. Steroid injection was found to be more effective than orthoses for the short term only in one study;<sup>[14]</sup> however, it was reported that this effect was not superior to orthoses for the long term.<sup>[20]</sup> Our study demonstrated that the use of wrist splints significantly reduces pain in patients with LE both at one and six months; however, an increase in grip strength and functional improvement was not observed in our study.

Corticosteroid injections, which are frequently used in LE treatment, have recently become debatable by suggesting frequent development of recurrence and not having long-term effects. Altay et al.<sup>[21]</sup> compared lidocaine injection and CS injection with lidocaine in patients with LE and did not demonstrate a significant difference between the groups at the end of one year besides a high rate of recovery in both groups. Krogh et al.<sup>[22]</sup> found no differences between CS and placebo injections for pain relief at eight weeks. In two studies comparing CS injection, physical therapy, and wait-and-see approach in patients with LE, it was

discovered that CS injections are more effective in acute periods; however, these effects decrease in the long term.<sup>[7,23]</sup> We determined in our study that CS injection was effective in LE treatment in terms of pain and grip strength both at one and six months. Therefore, CS injection was significantly effective for PRTEE pain and function in only the first month. Improvement with CS injection is in contradiction with the fact that active inflammation does not occur in LE etiopathogenesis. However, the formation of bleeding in the damaged tissue with needling technique during injection, its promotion regarding the improvement, and membrane-stabilizing effects of CS may explain the efficacy of CS in our study.<sup>[24]</sup> Although the recurrence of LE after CS injection is one of the controversial issues, there was no recurrence in any of the patients who received CS injection in our study. The highest decrease in VAS scores was observed in the first month in the CS injection group. In the short term, the pain-relieving effect of CS injection can lead to overuse of the elbow and cause recurrence. Therefore, the patient may be advised to prevent overuse of the elbow after CS injection to prevent recurrence.

As degeneration was determined rather than inflammation in LE pathogenesis, regenerative therapies have been focused on lately. These therapies are autologous growth factors, administered as autologous whole blood or platelet-rich plasma. It is aimed to trigger tendon regeneration by injecting autologous growth factors obtained from the patient's blood into the damaged area.<sup>[25]</sup> Alpha granules emerge by degradation of thrombocytes injected into the damaged area. Several growth factors (Platelet Derived Growth Factor, Transforming Growth Factor Beta, Vascular Endothelial Growth Factor, Epidermal Growth Factor, Insulin-Like Growth Factor, etc.) are released by the lysis of alpha granules. These growth factors enable tendon healing by stimulating cell proliferation, angiogenesis, chemotaxis, and remodeling.<sup>[26]</sup> Arik et al.<sup>[10]</sup> compared CS injection with AB injection in patients with LE. They followed up the patients for six months and reported that AB injection was more effective than CS injection in the long term in terms of pain, function, and grip strength. Chou et al.<sup>[27]</sup> reported that AB was significantly more effective than CS injections for LE in their study. In a meta-analysis, Sirico<sup>[28]</sup> found that the CS injections reduced the VAS pain score more than AB injections for the short term, yet no differences existed between groups for the medium and long term. He suggested a multiple therapy injection protocol consisting of CS injections for short-term pain relief along with AB injections for

long-term functional recovery. In our study, the AB injection group was similar to others for improvement in pain and grip strength. Whereas at six months, only the AB injection group significantly improved in regards to PRTEE, and only the CS injection was significantly effective for PRTEE pain and function at one month. The AB injection was more effective than the CS injection to improve functionality in the long term, although the CS injection led to faster pain improvement in accordance with previous studies.<sup>[10,11]</sup> Autologous blood contains growth factors that may be beneficial for tendon healing; however, this effect may not occur quickly but in the medium to long term. Thus, this extended period for healing may explain why VAS scores at six months were much lower than at one month in the AB group. Among the patients included in our study, a complication (hand drop) was observed in only one patient for whom AB injection was applied. An observational study using ultrasound showed that injected AB tended to distribute around the area of injection, which might decrease the effectiveness of the injection.<sup>[29]</sup> This effect may explain the possible radial nerve compression in the patient who developed hand drop after AB injection in our study.

Another regenerative treatment with increasing popularity in recent years is prolotherapy. In prolotherapy, hyperosmolar dextrose is injected into the ligaments and entheses of tendons, and natural healing mechanisms of the body are triggered by stimulating an inflammatory cascade. Additionally, increased dextrose in extracellular fluid stimulates cell proliferation and the production of growth factors. Consequently, the increase in mature collagen synthesis is improved, and the tendons and ligaments are reinforced.<sup>[30,31]</sup> There are limited studies available on prolotherapy in LE treatment. Scarpone et al.<sup>[14]</sup> randomly assigned 20 patients with chronic LE to two groups and administered 10% dextrose and 0.9 saline injection to the treatment group and 0.9 saline injection to the control group. In the patient group, they determined a distinct reduction in pain level and a distinct increase in grip strength. They demonstrated that this clinical improvement lasted for a year. Bayat et al.<sup>[32]</sup> reported that both CS injection and prolotherapy methods are effective, but dextrose prolotherapy was more effective over an extended period. Finally, in 2019, a review of Dwivedi et al.<sup>[33]</sup> reported beneficial effects of prolotherapy for upper extremity pathologies such as rotator cuff disease, LE, and hand osteoarthritis. They mentioned prolotherapy was safe and cost effective. In our study, we used 30% dextrose as an irritant solution and repeated the

injection two times every other month. We observed significant improvement in terms of pain, grip strength, and function in both the short and long term. We did not find a significant difference between prolotherapy, CS injection, and AB injection in LE treatment. Although it is not exactly known which irritant solution should be used in prolotherapy and how many times and how long the injections should be repeated, we preferred to apply prolotherapy for two sessions with one-month intervals.<sup>[34]</sup> Therefore, further randomized, controlled clinical trials involving an adequate number of patients and extended follow-up periods are necessary to reveal the effect of prolotherapy in LE treatment.

Our study is the first trial that compares CS injection, AB injection, and prolotherapy together, and it also directly compares AB injection and prolotherapy.

The main limitation of this study was the lack of an imaging modality such as ultrasonography for the diagnosis and treatment. Another limitation is that the follow-up time was six months. The final limitation is the lack of selection of patients according to occupation or the kind of sports activity that may affect outcomes.

In conclusion, CS injection, AB injection, and prolotherapy appear beneficial in LE treatment. It was demonstrated that the use of a wrist splint, although reducing the pain, does not provide an increase in grip strength and functional improvement. Further controlled studies are required to determine whether the improvement after injections is related to the injected substance or the treatment method.

**Ethics Committee Approval:** The study protocol was approved by the Ankara Training and Research Hospital Ethics Committee (No: 2013/4422). The study was conducted in accordance with the principles of the Declaration of Helsinki.

**Patient Consent for Publication:** A written informed consent was obtained from each patient.

**Data Sharing Statement:** The data that support the findings of this study are available from the corresponding author upon reasonable request.

**Author Contributions:** Conception or design of the work: SSK, GY.; Data collection; SSK, GY.; Data analysis and interpretation: HG, GY.; Drafting the article: SSK, GY, HG.; Critical revision of the article: HG, HG.

**Conflict of Interest:** The authors declared no conflicts of interest with respect to the authorship and/or publication of this article.

**Funding:** The authors received no financial support for the research and/or authorship of this article.

## REFERENCES

1. Kraushaar BS, Nirschl RP. Tendinosis of the elbow (tennis elbow). Clinical features and findings of histological, immunohistochemical, and electron microscopy studies. *J Bone Joint Surg [Am]* 1999;81:259-78.
2. Shiri R, Viikari-Juntura E, Varonen H, Heliövaara M. Prevalence and determinants of lateral and medial epicondylitis: A population study. *Am J Epidemiol* 2006;164:1065-74.
3. Coonrad RW, Hooper WR. Tennis elbow: Its course, natural history, conservative and surgical management. *J Bone Joint Surg [Am]* 1973;55:1177-82.
4. Keus SHJ, Smidt N, Assendelft WJJ. Treatment of lateral epicondylitis in general practice. *European Journal of General Practice* 2002;8:71-2.
5. Mardani-Kivi M, Karimi-Mobarakeh M, Karimi A, Akhoondzadeh N, Saheb-Ekhtiari K, Hashemi-Motlagh K, et al. The effects of corticosteroid injection versus local anesthetic injection in the treatment of lateral epicondylitis: A randomized single-blinded clinical trial. *Arch Orthop Trauma Surg* 2013;133:757-63.
6. Labelle H, Guibert R, Joncas J, Newman N, Fallaha M, Rivard CH. Lack of scientific evidence for the treatment of lateral epicondylitis of the elbow. An attempted meta-analysis. *J Bone Joint Surg [Br]* 1992;74:646-51.
7. Smidt N, van der Windt DA, Assendelft WJ, Devillé WL, Korthals-de Bos IB, Bouter LM. Corticosteroid injections, physiotherapy, or a wait-and-see policy for lateral epicondylitis: A randomised controlled trial. *Lancet* 2002;359:657-62.
8. Rabago D, Best TM, Zgierska AE, Zeisig E, Ryan M, Crane D. A systematic review of four injection therapies for lateral epicondylitis: Prolotherapy, polidocanol, whole blood and platelet-rich plasma. *Br J Sports Med* 2009;43:471-81.
9. Houck DA, Kraeutler MJ, Thornton LB, McCarty EC, Bravman JT. Treatment of lateral epicondylitis with autologous blood, platelet-rich plasma, or corticosteroid injections: A systematic review of overlapping meta-analyses. *Orthop J Sports Med* 2019;7:2325967119831052.
10. Arik HO, Kose O, Guler F, Deniz G, Egerci OF, Ucar M. Injection of autologous blood versus corticosteroid for lateral epicondylitis: A randomised controlled study. *J Orthop Surg (Hong Kong)* 2014;22:333-7.
11. Bostan B, Balta O, Aşçı M, Aytekin K, Eser E. Autologous blood injection works for recalcitrant lateral epicondylitis. *Balkan Med J* 2016;33:216-20.
12. Ozturan KE, Yucel I, Cakici H, Guven M, Sungur I. Autologous blood and corticosteroid injection and extracorporeal shock wave therapy in the treatment of lateral epicondylitis. *Orthopedics* 2010;33:84-91.
13. Altan L, Ercan I, Konur S. Reliability and validity of Turkish version of the patient rated tennis elbow evaluation. *Rheumatol Int* 2010;30:1049-54.
14. Scarpone M, Rabago DP, Zgierska A, Arbogast G, Snell E. The efficacy of prolotherapy for lateral epicondylitis: A pilot study. *Clin J Sport Med* 2008;18:248-54.
15. Sharma P, Maffulli N. Biology of tendon injury: Healing, modeling and remodeling. *J Musculoskelet Neuronal Interact* 2006;6:181-90.
16. Ölmez N, Memiş A. Evidence based data for management of lateral epicondylitis: Review. *Turkiye Klinikleri Journal of Medical Sciences* 2010;30:303-11.
17. Altan L, Kanat E. Conservative treatment of lateral epicondylitis: Comparison of two different orthotic devices. *Clin Rheumatol* 2008;27:1015-9.
18. Garg R, Adamson GJ, Dawson PA, Shankwiler JA, Pink MM. A prospective randomized study comparing a forearm strap brace versus a wrist splint for the treatment of lateral epicondylitis. *J Shoulder Elbow Surg* 2010;19:508-12.
19. Belhan O, Karakurt L. Humerus lateral epikondilit tedavisinde lokal steroid enjeksiyonu ile lateral epikondilit bandajının etkinliğinin karşılaştırılması. *Firat Tıp Dergisi* 2008;13:24-7.
20. Struijs PA, Smidt N, Arola H, van Dijk CN, Buchbinder R, Assendelft WJ. Orthotic devices for tennis elbow: A systematic review. *Br J Gen Pract* 2001;51:924-9.
21. Altay T, Günel I, Oztürk H. Local injection treatment for lateral epicondylitis. *Clin Orthop Relat Res* 2002;(398):127-30.
22. Krogh TP, Bartels EM, Ellingsen T, Stengaard-Pedersen K, Buchbinder R, Fredberg U, et al. Comparative effectiveness of injection therapies in lateral epicondylitis: A systematic review and network meta-analysis of randomized controlled trials. *Am J Sports Med* 2013;41:1435-46.
23. Bisset L, Beller E, Jull G, Brooks P, Darnell R, Vicenzino B. Mobilisation with movement and exercise, corticosteroid injection, or wait and see for tennis elbow: Randomised trial. *BMJ* 2006;333:939.
24. Johansson A, Hao J, Sjölund B. Local corticosteroid application blocks transmission in normal nociceptive C-fibres. *Acta Anaesthesiol Scand* 1990;34:335-8.
25. de Vos RJ, van Veldhoven PL, Moen MH, Weir A, Tol JL, Maffulli N. Autologous growth factor injections in chronic tendinopathy: A systematic review. *Br Med Bull* 2010;95:63-77.
26. Andia I, Sanchez M, Maffulli N. Tendon healing and platelet-rich plasma therapies. *Expert Opin Biol Ther* 2010;10:1415-26.
27. Chou LC, Liou TH, Kuan YC, Huang YH, Chen HC. Autologous blood injection for treatment of lateral epicondylitis: A meta-analysis of randomized controlled trials. *Phys Ther Sport* 2016;18:68-73.
28. Sirico F, Ricca F, DI Meglio F, Nurzynska D, Castaldo C, Spera R, et al. Local corticosteroid versus autologous blood injections in lateral epicondylitis: Meta-analysis of randomized controlled trials. *Eur J Phys Rehabil Med* 2017;53:483-91.
29. Loftus ML, Endo Y, Adler RS. Retrospective analysis of postinjection ultrasound imaging after platelet-rich plasma or autologous blood: Observational review of anatomic distribution of injected material. *AJR Am J Roentgenol* 2012;199:W501-5.
30. Hauser RA, Hauser MA, Baird NM. Evidence-based use of dextrose prolotherapy for musculoskeletal pain: A scientific literature review. *Journal of Prolotherapy* 2011;3:765-89.
31. Jensen KT, Rabago DP, Best TM, Patterson JJ, Vanderby R Jr. Early inflammatory response of knee ligaments to prolotherapy in a rat model. *J Orthop Res* 2008;26:816-23.



32. Bayat M, Raeissadat SA, Mortazavian Babaki M, Rahimi-Dehgolan S. Is dextrose prolotherapy superior to corticosteroid injection in patients with chronic lateral epicondylitis?: A randomized clinical trial. *Orthop Res Rev* 2019;11:167-75.
33. Dwivedi S, Sobel AD, DaSilva MF, Akelman E. Utility of prolotherapy for upper extremity pathology. *J Hand Surg Am* 2019;44:236-9.
34. Carayannopoulos A, Borg-Stein J, Sokolof J, Meleger A, Rosenberg D. Prolotherapy versus corticosteroid injections for the treatment of lateral epicondylosis: A randomized controlled trial. *PM R* 2011;3:706-15.