



Case Report

Alternative treatment of resistant hypoparathyroidism by intermittent infusion of teriparatide using an insulin pump: A case report

Zafer Pekkolay¹, Faruk Kılınc², Hikmet Soylu¹, Belma Balsak¹, Mehmet Güven¹, Şadiye Altun Tuzcu³, Ali Veysel Kara¹, Alpaslan Kemal Tuzcu¹

¹Department of Internal Medicine, Dicle University School of Medicine, Diyarbakır, Turkey

²Department of Adult Endocrinology, Fırat University School of Medicine, Elazığ, Turkey

³Department of Nuclear Medicine, Gazi Yaşargil Training and Research Hospital, Diyarbakır, Turkey

Received: February 19, 2018 Accepted: June 14, 2018 Published online: May 02, 2018

ABSTRACT

Hypoparathyroidism usually responds to oral active vitamin D and calcium, but, although rare, some patients do not respond to this treatment. A 47-year-old Caucasian female presented to our medical unit with classical oral treatment-resistant hypocalcemia after thyroidectomy. Teriparatide was infused through the insulin pump with dosage set to 1 unit which equals to 2.5 µg of teriparatide. In conclusion, intermittent subcutaneous infusion of teriparatide using an insulin pump is a safe and effective treatment modality to ensure normocalcemic conditions in patients with classical treatment-resistant hypoparathyroidism.

Keywords: Hypoparathyroidism; pump infusion; teriparatide.

Hypoparathyroidism is characterized by low calcium and low parathyroid hormone (PTH) levels. Hyperphosphatemia, hypercalciuria, and reduced active vitamin D are associated with hypoparathyroidism.^[1] The main clinical features of the disease are hypocalcemic symptoms such as perioral numbness, paresthesia, and carpopedal muscle spasms. In addition, some severe and potentially life-threatening complications such as laryngeal spasms, tetany and seizures may occur during the course of hypoparathyroidism. The most common cause of hypoparathyroidism is accidental damage to the parathyroid glands during thyroid surgery.^[2]

There are no formal guidelines for hypoparathyroidism management. In the acute setting, intravenous administration of calcium may be necessary. Based on current clinical evidence, the main goal of treatment is to improve the symptoms of hypocalcemia, to keep the serum calcium within the low normal range, and to avoid hypercalcemia

and hypercalciuria, regardless of etiology by providing standard hypoparathyroidism treatment with oral calcium and vitamin D supplements at different doses.^[3] In 2015, the United States Food and Drug Administration (FDA) approved the use of recombinant human PTH (1-84) in treating patients with classical treatment-resistant hypoparathyroidism.^[4,5] It is expected that the PTH analogues would be mainstay for the treatment for regaining normal physiology. Although teriparatide, a recombinant human PTH (1-34), is widely used in the treatment of osteoporosis, there is a limited number of literature data on its use for hypoparathyroidism. A study comparing parenteral teriparatide with classical oral treatment showed that parenteral therapy was more effective in reducing hypercalciuria and improving quality of life.^[6]

In addition, when once-daily regimen was compared with twice-daily regimen, the latter was found to be more effective.^[7] The long-term use of

Corresponding author: Zafer Pekkolay, MD. Dicle Üniversitesi Tıp Fakültesi İç Hastalıkları Anabilim Dalı, 21280 Sur, Diyarbakır, Turkey.

e-mail: drpekkolay@gmail.com

Cite this article as:

Pekkolay Z, Kılınc F, Soylu H, Balsak B, Güven M, Altun Tuzcu Ş, et al. Alternative treatment of resistant hypoparathyroidism by intermittent infusion of teriparatide using an insulin pump: A case report. Turk J Phys Med Rehab 2019;65(2):198-201.

39th Turkey Congress of Endocrinology and Metabolic Diseases, May 3-7, 2017, Antalya, Turkey.

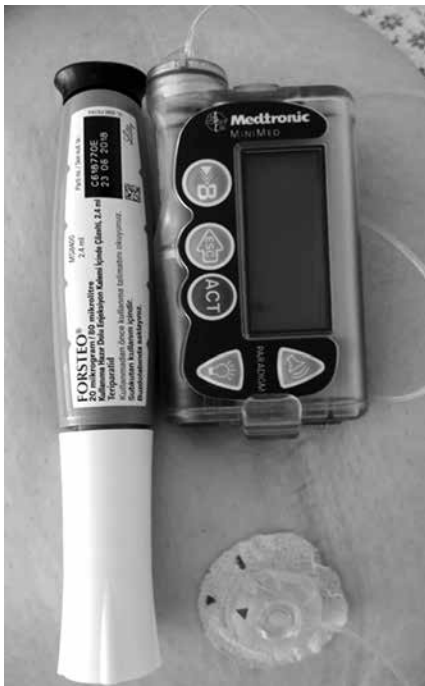

Figure 1. Teriparatide through an insulin pump.

teriparatide was also shown to be safe and effective. Moreover, it was observed that, compared to single-dose subcutaneous teriparatide injection, continuous infusion of teriparatide via an insulin pump was more effective.^[8] In another study, Puig-Domingo et al.^[9] succeeded to treat the treatment-resistant hypoparathyroidism through PTH in short-interval pulse-type to mimic physiological PTH release.

To the best of our knowledge, this is the first case in Turkey in whom teriparatide was administered

for classical treatment-resistant hypoparathyroidism using an insulin pump and succeeded in achieving normocalcemia.

CASE REPORT

A 47-year-old Caucasian female patient presented with paresthesia and carpedal spasm. The patient underwent total thyroidectomy due to multinodular goitre two years ago. Thereafter, the patient developed postoperative hypoparathyroidism and was hospitalized several times in the emergency setting and treated for correcting hypocalcemia. She was admitted to the Endocrinology Department due to resistant hypoparathyroidism. On admission, her physical examination results were normal, except for thyroidectomy scars and carpedal spasm. The laboratory values were as follows: PTH 8.6 (15-65) pg/dL, serum calcium 6.4 (8.5-10.5) mg/dL, phosphorus 5.4 (2.7-4.8) mg/dL, and albumin 3.3 (4-5) mg/dL. Although she was on regular medication of calcitriol 6 µg/day, elemental calcium 12 g/day, oral 1,25-OH vitamin D and oral magnesium, hypocalcemia was persistent. Normocalcemia was achieved by parenteral calcium administration in our clinic. Celiac panel and small bowel biopsy were carried out for exclusion of malabsorption syndrome and were found to be negative. Since hypercalciuria (960 mg/day) was detected, the patient was administered thiazide diuretic. Parenteral active vitamin D was administered to the patient rather than oral vitamin D therapy. However, hypocalcemia was unable to be corrected. Therefore, teriparatide was administered. We initiated once daily 20 µg subcutaneous injection of recombinant human PTH (1-34)

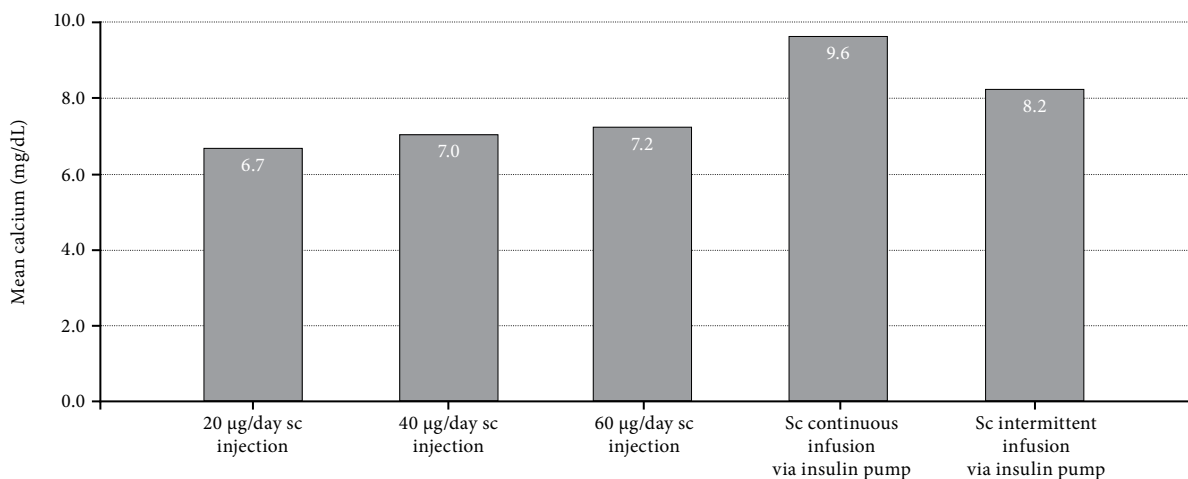


Figure 2. Treatment methods and calcium level. Sc: Subcutaneous.

(Teriparatide; Lilly France S.A.S, Forsteo®, Fegersheim, France). Although the dose was titrated up to 60 µg/day in three equal doses, hypocalcemia still remained uncorrected. Therefore, continuous teriparatide infusion using an insulin pump was suggested. The insulin pump was calibrated such that 1 unit (Minimed Medtronic) equals 2.5 µg of teriparatide (Figure 1). Normocalcemia was achieved with continuous dose infusion (1 unit/hour, totally 60 µg teriparatide). However, during follow-up, the patient experienced hypercalcemia due to this treatment. Due to the presence of hypercalcemia, the dose of teriparatide infusion was adjusted to mimic physiological PTH release as 1.1 unit for one-hour infusion and one-hour off (totally 33 µg/day teriparatide) and normocalcemia was achieved (Figure 2). The level of 1,25-dihydroxy vitamin D level was normal during teriparatide treatment after which the patient's calcium levels improved. Oral calcium and active vitamin D requirements decreased. After several admissions to the hospital for two years, the patient was eventually discharged with this treatment. The patient did not need any additional therapy for the next seven months after discharge. The patient has been still waiting for parathyroid transplantation under this therapy.

DISCUSSION

Hypoparathyroidism, which does not respond to active vitamin D, is a very rare condition. The success rate of parathyroid transplantation is low worldwide, as most attempts have resulted in transplant rejection.^[10] Therefore, it seems reasonable to use PTH analogues in such patients.

Previous use of teriparatide has focused more on non-normocalcemic effects.^[11] There are also several publications on the use of PTH analogues, since its approval by the FDA in recent years.^[5,12] Studies on PTH (1-34) have shown that subcutaneous administration is more effective than classical oral treatment. Meanwhile, better results were obtained with the continuous infusion via insulin pump than with the subcutaneous injection. However, no resistant hypocalcemic patients were reported in these studies.^[13] Andrysiak-Mamos et al.^[14] found that three patients with postoperative resistance hypoparathyroidism were treated with subcutaneous 20 to 80 µg/day teriparatide successfully.^[14] Díaz-Soto et al.^[15] reported teriparatide infusion through a pump in a patient with hypoparathyroidism resistant to vitamin D treatment. Teriparatide was infused in five to seven impulse doses per hour. The treatment

was observed to be effective and safe for five years. Saraff et al.^[16] provided normocalcemia in four patients through subcutaneous teriparatide infusion, and observed no side effects for the first year.^[16] In our case, we also achieved successful results with intermittent infusion.

In conclusion, we believe that teriparatide, a PTH analogue, provides normocalcemia with intermittent subcutaneous infusion in patients with classical treatment-resistant hypoparathyroidism. Since in the literature review, no case in whom normocalcemia is able to be achieved with intermittent constant one hourly infusion of teriparatide is available, this is the first case in whom normocalcemia was achieved by intermittent infusion of PTH 1-34 in Turkey.

Declaration of conflicting interests

The authors declared no conflicts of interest with respect to the authorship and/or publication of this article.

Funding

The authors received no financial support for the research and/or authorship of this article.

REFERENCES

1. Bilezikian JP, Khan A, Potts JT Jr, Brandi ML, Clarke BL, Shoback D, et al. Hypoparathyroidism in the adult: epidemiology, diagnosis, pathophysiology, target-organ involvement, treatment, and challenges for future research. *J Bone Miner Res* 2011;26:2317-37.
2. Shoback DM, Bilezikian JP, Costa AG, Dempster D, Dralle H, Khan AA, et al. Presentation of Hypoparathyroidism: Etiologies and Clinical Features. *J Clin Endocrinol Metab* 2016;101:2300-12.
3. Shoback D. Clinical practice. Hypoparathyroidism. *N Engl J Med* 2008;359:391-403.
4. Cusano NE, Rubin MR, Sliney J Jr, Bilezikian JP. Mini-review: new therapeutic options in hypoparathyroidism. *Endocrine* 2012;41:410-4.
5. Marcucci G, Della Pepa G, Brandi ML. Drug safety evaluation of parathyroid hormone for hypocalcemia in patients with hypoparathyroidism. *Expert Opin Drug Saf* 2017;16:617-25.
6. Winer KK, Sinaii N, Peterson D, Sainz B Jr, Cutler GB Jr. Effects of once versus twice-daily parathyroid hormone 1-34 therapy in children with hypoparathyroidism. *J Clin Endocrinol Metab* 2008;93:3389-95.
7. Winer KK, Yanovski JA, Sarani B, Cutler GB Jr. A randomized, cross-over trial of once-daily versus twice-daily parathyroid hormone 1-34 in treatment of hypoparathyroidism. *J Clin Endocrinol Metab* 1998;83:3480-6.
8. Winer KK, Zhang B, Shrader JA, Peterson D, Smith M, Albert PS, et al. Synthetic human parathyroid hormone 1-34 replacement therapy: a randomized crossover trial comparing pump versus injections in the treatment of chronic hypoparathyroidism. *J Clin Endocrinol Metab* 2012;97:391-9.

9. Puig-Domingo M, Díaz G, Nicolau J, Fernández C, Rueda S, Halperin I. Successful treatment of vitamin D unresponsive hypoparathyroidism with multipulse subcutaneous infusion of teriparatide. *Eur J Endocrinol* 2008;159:653-7.
10. Torregrosa NM, Rodríguez JM, Llorente S, Balsalobre MD, Rios A, Jimeno L, et al. Definitive treatment for persistent hypoparathyroidism in a kidney transplant patient: parathyroid allotransplantation. *Thyroid* 2005;15:1299-302.
11. Upreti V, Somani S, Kotwal N. Efficacy of Teriparatide in Patients with Hypoparathyroidism: A Prospective, Open-label Study. *Indian J Endocrinol Metab* 2017;21:415-8.
12. Cusano NE, Rubin MR, Bilezikian JP. PTH(1-84) replacement therapy for the treatment of hypoparathyroidism. *Expert Rev Endocrinol Metab* 2015;10:5-13.
13. Bilezikian JP, Brandi ML, Cusano NE, Mannstadt M, Rejnmark L, Rizzoli R, et al. Management of Hypoparathyroidism: Present and Future. *J Clin Endocrinol Metab* 2016;101:2313-24.
14. Andrysiak-Mamos E, Żochowska E, Kaźmierczyk-Puchalska A, Popow M, Kaczmarek-Turek D, Pachucki J, et al. Treatment of severe life threatening hypocalcemia with recombinant human teriparatide in patients with postoperative hypoparathyroidism - a case series. *Endokrynol Pol* 2016;67:403-12.
15. Díaz-Soto G, Mora-Porta M, Nicolau J, Perea V, Halperin I, Puig-Domingo M. Efficacy and safety of long term treatment of unresponsive hypoparathyroidism using multipulse subcutaneous infusion of teriparatide. *Horm Metab Res* 2012;44:708-10.
16. Saraff V, Rothenbuhler A, Högl W, Linglart A. Continuous Subcutaneous Recombinant Parathyroid Hormone (1-34) Infusion in the Management of Childhood Hypoparathyroidism Associated with Malabsorption. *Horm Res Paediatr* 2018;89:271-7.