



Application of kinesiотaping to treat symptomatic bipartite patella

Semptomatik bipartite patella tedavisinde kinezyolojik bantlama uygulaması

Aylin Dikici,¹ Ömer Dikici,² Özlem Solak²

¹Department of Physical Medicine and Rehabilitation, Afyon State Hospital, Afyonkarahisar, Turkey

²Department of Physical Medicine and Rehabilitation, Medical Faculty of Afyon Kocatepe University, Afyonkarahisar, Turkey

Received / *Geliş tarihi:* August 2014 Accepted / *Kabul tarihi:* November 2014

ABSTRACT

Bipartite patella is an accessory bone that can be incidentally observed during radiographic examinations. Hereby we present the efficiency of kinesiотaping treatment to the 32-year-old female patient with a unilateral symptomatic bipartite patella. Her pain worsened with movement. There was sensitivity at the patella upper lateral edge during palpation. She was treated with exercise and kinesiотaping to the left knee every five days for five sessions. The visual analog scale score of the patient decreased.

Keywords: Anterior knee pain; kinesiотaping; bipartite patella.

ÖZ

Bipartite patella radyografik incelemelerde rastlantısal olarak görülebilen aksesuar bir kemiktir. Bu yazıda tek taraflı semptomatik bipartite patellalı 32 yaşında kadın hastaya uyguladığımız kinezyolojik bantlama tedavisinin etkinliği sunuldu. Hastanın ağrısı hareket ettikçe artıyordu. Palpasyonla patella üst yan uçta hassasiyet vardı. Hastaya egzersiz ile birlikte beş seans şeklinde beş günde bir sol dize kinezyolojik bantlama tedavisi uygulandı. Hastanın görsel ağrı skala skoru geriledi.

Anabtar sözcükler: Ön diz ağrısı; kinezyolojik bantlama; bipartite patella.

The patella, which is the largest sesamoid bone in our body, develops from a single ossification center in 77% of children, whereas in 23% of children this bone develops from 2 or 3 ossification centers. Generally, the primary ossification center is formed between the ages of 4-6, and the other centers emerge by the age of 12. Mostly, in the advancing years these centers fuse together. However, fusion might not be observed in 2-6% of these centers. This situation may lead to bipartite or tripartite patella.^[1]

Bipartite patella is frequently asymptomatic. It is usually observed incidentally in graphs. Only 2% of the cases are symptomatic and painful. Symptoms are usually seen in adolescent males, athletes and soldiers due to excessive usage and trauma during adolescence.^[2]

Kinesiотaping (KT) technique was developed in the early 1970's by Dr. Kenzo Kase in order to prevent restrictions that were formed during joint movements or functional activities which were deemed as undesirable effects of standard banding and taping applications.^[3,4] The presence of some positive results obtained from studies evaluating the clinical efficiency of KT treatment recently have been emphasized.^[3,4] These effects comprise regulating the function of muscles that are weak; regulating the excessive subcutaneous edema and impaired circulation by stimulating lymphatic and blood circulation systems; reducing pain by way of neurological suppression; facilitating the movement of fascia and tendons by reducing abnormal muscle tension; repositioning subluxated joints and increasing proprioception by

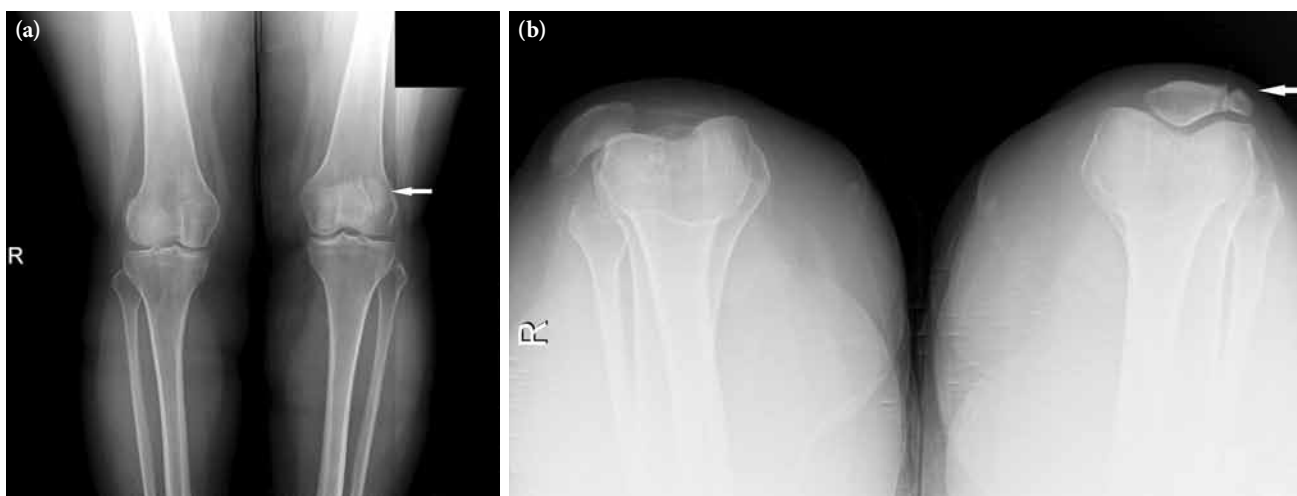

Figure 1. (a) Anteroposterior knee and (b) skyline patella view of both knees radiograph.

way of cutaneous mechanoreceptors.^[5] We hereby present the effectiveness of the KT treatment that has been applied to the female patient suffering from symptomatic unilateral bipartite patella.

CASE REPORT

A 32-year-old female patient applied to our polyclinic due to severe left anterior upper knee pain. The pain that the patient has been suffering, was alleviated in the last two months and has since increased even more when the patient knelt down or climbed stairs. The patient did not have a history of trauma. The patient expressed that although she had been taking various non-steroid anti-inflammatory drugs (NSAIDs) for a long period of time, her pain was not reduced. No specific situation was present in her background history. No kind of swelling or deformity was found during physical examination. The passive and active ranges of motions were full. Sensitivity was present at the patella upper lateral edge

during palpation. Specific knee tests such as patellar grind and grating tests were carried out and they were determined to be positive. Ligament laxity tests, meniscus tests and patellar tilt tests were negative. The lower extremity neurologic examination was normal. The laboratory tests such as hemogram, erythrocyte sedimentation rate (ESR), C reactive protein, serum calcium, phosphorus, alkaline phosphatase levels were at normal limits. The anteroposterior knee and skyline patella radiographs have been evaluated and she was diagnosed with type 3 bipartite patella according to Saupe's classification (Figure 1).^[6] A written informed consent was obtained from the patient.

Functional correction technique was used at the knee region of the patient and two Y tapes were applied as KT treatment. During the first taping, the knee was slightly flexed. The tape was adhered from the quadriceps muscle until the patella upper end with slight flexing. Following this, the knee was flexed maximum and the two ends of the Y tape were

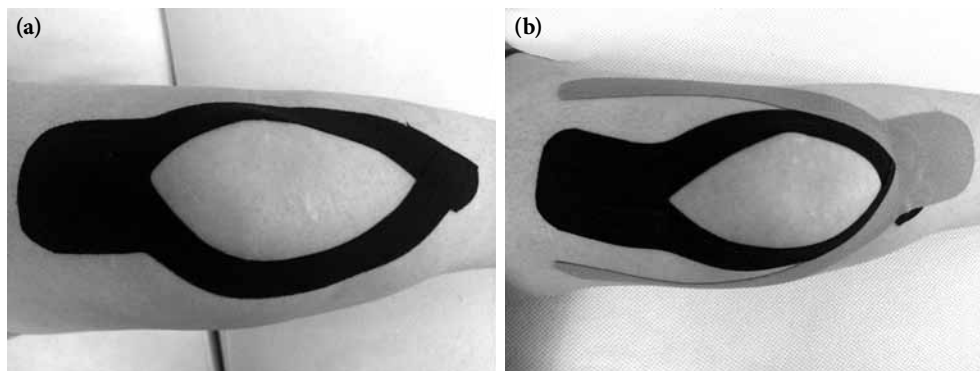


Figure 2. Kinesiotape application.

inserted from the medial and lateral of the patella with slight stretching and were adhered to the tuberosity tibia without stretching. In the second taping session the knee was brought to slight flexion, and taping was started from the tuberosity tibia and extended to the patella lower end with slight stretching. Following this, the knee was brought to maximum flexion and the medial tape was taped to the vastus lateralis obliquus, and the lateral tape was taped to the vastus lateralis muscle with slight stretching (Figure 2). Additionally, the patient was advised to rest and given an exercise program that contained quadriceps and hamstring stretching exercises, and quadriceps strengthening exercises. Kinesiotaping treatment was applied to the patient every five days for a total of five sessions. During the pain evaluation prior to treatment, the visual analog scale (VAS) score was calculated as 90 mm; whereas after the first session of taping the VAS score was reduced to 0 mm. After the fifth session, she did not feel any pain. The patient was advised to carry on her exercise treatment and was called for a control examination a month later. During the first month examination, the patient informed us that she had slight pain only when she knelt down and she needed to use only an analgesic to relieve such pain. She came to the outpatient clinic for examination on the third month and she claimed that she was pain free.

DISCUSSION

Bipartite patella is usually observed incidentally during radiographic examinations and it has been classified into three types by Saupé: type 1 at the sub polar patella (5%), type 2 at the patella lateral edge (20%), type 3 at the superolateral (75%).^[6] Although bilateral cases are rarely observed, it is observed nine times more often in men when compared to women. The graph taken of our patient was compliant with type 3, which is the most frequently seen type of bipartite patella (Figure 1).

It is thought that pain is formed in two ways during symptomatic bipartite patella; which is pain that increases in stages based on activity or sudden pain following trauma.^[7] The pain is frequently seen at the anterior knee region. It is directly related with kneeling down or sudden flexing movement. Pain could be triggered especially by activities such as climbing stairs, walking or jumping.^[1] Our patient's pain was severe especially when she knelt down.

Although the treatment type of symptomatic bipartite patella is chosen according to the anamnesis and clinic of the patient, most of the patients benefit

from conservative treatment. During conservative treatment, the patients are advised to rest, to reduce sport, are given NSAID, corticosteroid injection together with local anesthetics, especially quadriceps and hamstring stretching exercises, physical treatment modalities and dynamic patellar brace treatment. There are studies reporting a decrease in acute knee pain by bracing the knee at 30 degree flexion position due to reducing the retraction effect of the vastus lateralis muscle to the superolateral side.^[8,9] Despite long-term conservative treatment lasting more than six months, those individuals with resistant or increasing pain, who need to continue their sports activities, and who are severely restricted in their daily activities could be treated surgically. Surgical treatment methods comprise methods such as; painful fragment excision, lateral retinacular relaxation, vastus lateralis relaxation, bone grafting or internal fixation of non-graft patellar fragments.^[2,10-12] Our patient had been receiving NSAID treatment for a long-term and her pain had become more severe.

The KT (kinesiotaping technique) was developed in the early 1970s by Dr. Kenzo Kase, who is a Japanese chiropractor and acupuncture specialist. Although standard band and tape applications support joint and muscle structures, they also restrict functional activities and joint motions. Moreover, these taping methods may slow down the healing of the damaged tissue due to their compressive effect on the tissue and do not support deep tissues such as fascia. Whereas KT, is a taping method that has similar flexibility and structural characteristics to human skin and this taping does not restrict the motion of joints.^[3] Some kinesiological tapes can extend up to 140% more than their normal lengths and constant tension is applied to the dermis and it is not possible for classic tapes to stretch.^[13] This characteristic is especially important in terms of the applicability of KT treatment in young patients and patients with an active life. In the recent years, studies are present showing that KT treatment is an effective method in treating anterior knee pain such as patellofemoral pain syndrome.^[14,15] For this reason, we treated our patient with a diagnosis of bipartite patella by KT and have observed that it is an effective treatment modality in reducing anterior knee pain in this patient.

In conclusion, KT is an effective method in decreasing anterior knee pain that can be used in symptomatic bipartite patella patients. This treatment could reduce the number of surgical operations in such cases. Moreover, it is more practical in application compared to orthosis and bracing treatments especially

for young people or individuals who have an active lifestyle. However, more randomized controlled studies with longer follow-up periods and with larger sample sizes are needed in order to support our data.

Declaration of conflicting interests

The authors declared no conflicts of interest with respect to the authorship and/or publication of this article.

Funding

The authors received no financial support for the research and/or authorship of this article.

REFERENCES

1. Gaheer RS, Kapoor S, Rysavy M. Contemporary management of symptomatic bipartite patella. *Orthopedics* 2009;32:843-9.
2. Weckström M, Parviainen M, Pihlajamäki HK. Excision of painful bipartite patella: good long-term outcome in young adults. *Clin Orthop Relat Res* 2008;466:2848-55.
3. Kase K, Wallis J, Kase T. Clinical therapeutic application of the kinesiotopeing method. Tokyo: Ken Ikai Co Ltd; 2003.
4. Çeliker R, Güven Z, Aydoğ T, Bağıs S, Atalay A, Yağcı HC, et al. The kinesiologic taping technique and its applications. *Turk J Phys Med Rehab* 2011;57:225-35.
5. Williams S, Whatman C, Hume PA, Sheerin K. Kinesio taping in treatment and prevention of sports injuries: a meta-analysis of the evidence for its effectiveness. *Sports Med* 2012;42:153-64.
6. Saupé H. Primäre Krochenmark serelung der kniescheibe. *Deutsche Z Chir* 1943;258:386-92.
7. Carney J, Thompson D, O'Daniel J, Cassidy J. Carney J, Thompson D, O'Daniel J, Cassidy J. *Am J Orthop (Belle Mead NJ)* 2010;39:40-3.
8. Kumahashi N, Uchio Y, Iwasa J, Kawasaki K, Adachi N, Ochi M. Bone union of painful bipartite patella after treatment with low-intensity pulsed ultrasound: report of two cases. *Knee* 2008;15:50-3.
9. Marya KM, Yadav V, Devagan A, Kundu ZS. Painful bilateral bipartite patellae--case report. *Indian J Med Sci* 2003;57:66-7.
10. Enomoto H, Nagosi N, Okada E, Ota N, Iwabu S, Kamiishi S. Hemilaterally symptomatic bipartite patella associated with bone erosions arising from a gouty tophus: a case report. *Knee* 2006;13:474-7.
11. Mori Y, Okumo H, Iketani H, Kuroki Y. Efficacy of lateral retinacular release for painful bipartite patella. *Am J Sports Med* 1995;23:13-8.
12. Adachi N, Ochi M, Yamaguchi H, Uchio Y, Kuriwaka M. Vastus lateralis release for painful bipartite patella. *Arthroscopy* 2002;18:404-11.
13. Kalichman L, Vered E, Volchek L. Relieving symptoms of meralgia paresthetica using Kinesio taping: a pilot study. *Arch Phys Med Rehabil* 2010;91:1137-9.
14. Akbaş E, Atay AO, Yüksel I. The effects of additional kinesiotopeing over exercise in the treatment of patellofemoral pain syndrome. *Acta Orthop Traumatol Turc* 2011;45:335-41.
15. Montalvo AM, Buckley WE, Sebastianelli W, Vairo GL. An Evidence-Based Practice Approach to the Efficacy of Kinesio Taping for Improving Pain and Quadriceps Performance in Physically-Active Patellofemoral Pain Syndrome Patients. *J Nov Physiother* 2013;3:1-6.